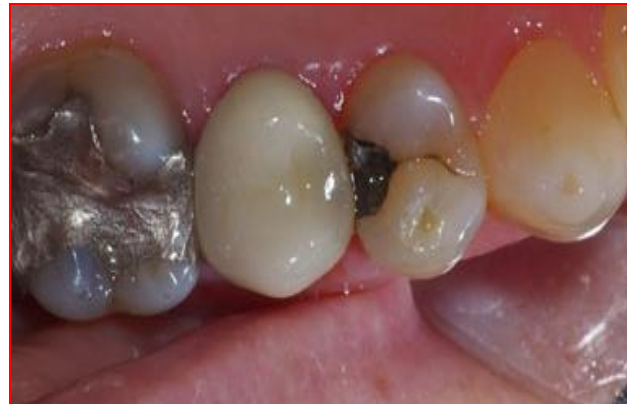
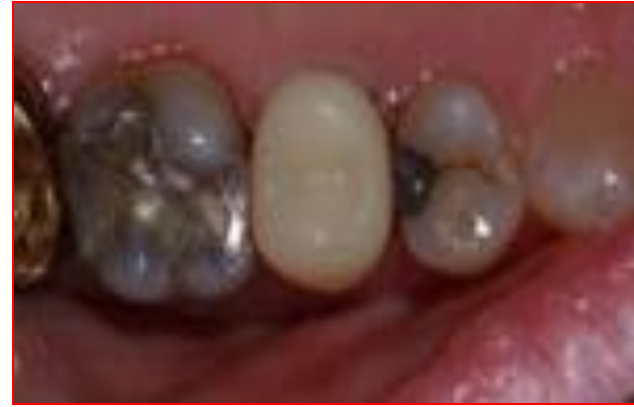
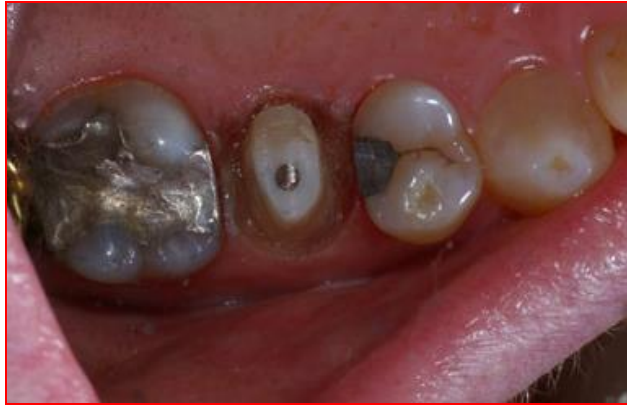Temporary Restoration (provisional restoration)

Dr. Emad Farhan Alkalidi
MSc, PhD

What's a temporary crown restoration?

A crown restoration that is used in fixed prosthodontics during the interim between tooth preparation and final placement of the definitive crown restoration.



Objectives of provisional restoration:

- 1. protect the tooth from pain stimuli as a result of thermal, chemical, and osmotic changes in the mouth.**
- 2. prevent sensitivity and further irritation to the pulp since a certain degree of pulp trauma is inevitable during tooth preparation because of the sectioning of the dentinal tubules.**
- 3. prevent movement of the prepared, adjacent, and opposing teeth. i.e., to prevent supraeruption and drifting.**
- 4. protect the gingival tissue from irritation and food impaction.**
- 5. provide esthetic, phonetic, and function.**
- 6. prevent tooth fracture.**

Requirements of an optimum provisional restoration:

The image shows three 3D models of teeth arranged in a row from left to right. Each tooth is highlighted with a black oval. The first tooth on the left is labeled 'I. Biologic.' and shows a natural tooth with a crown. The middle tooth is labeled 'II. Mechanical.' and shows a tooth with a crown that has a more pronounced, rounded shape. The third tooth on the right is labeled 'III. Esthetic.' and shows a tooth with a crown that is highly polished and has a very smooth, natural-looking appearance. The background is a light blue gradient.

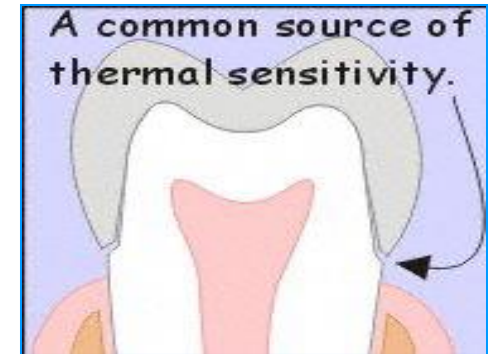I. Biologic.

II. Mechanical.

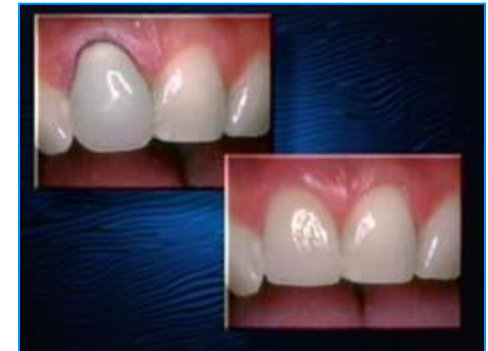III. Esthetic.

Requirements of an optimum provisional restoration:

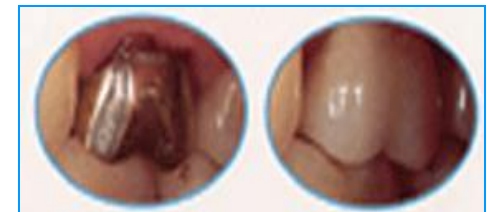1. A provisional restoration must seal and insulate the prepared tooth surface from the oral environment to prevent sensitivity and further irritation to the pulp.



2. A provisional restoration must have good marginal fit, proper contour, and a smooth surface to maintain the health of the gingival tissue and facilitate plaque control by the patient.

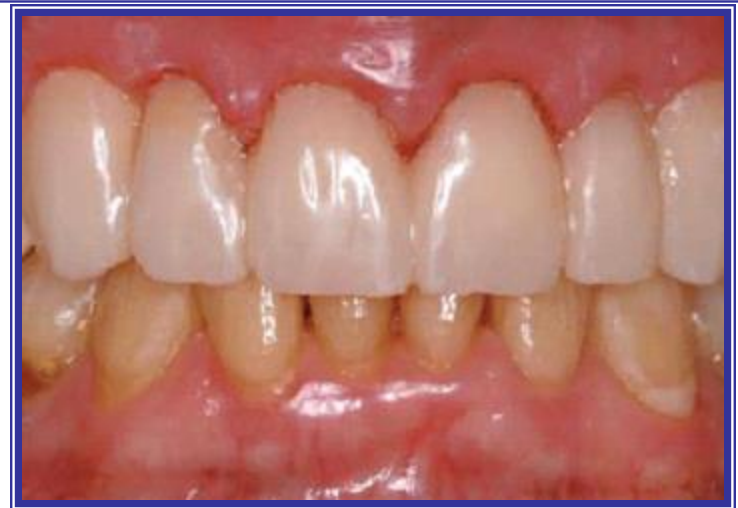
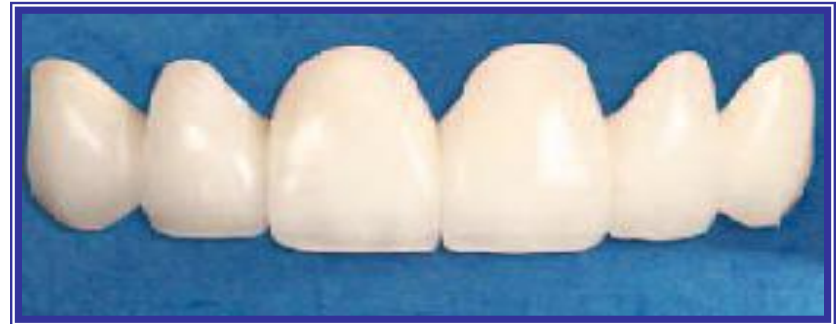
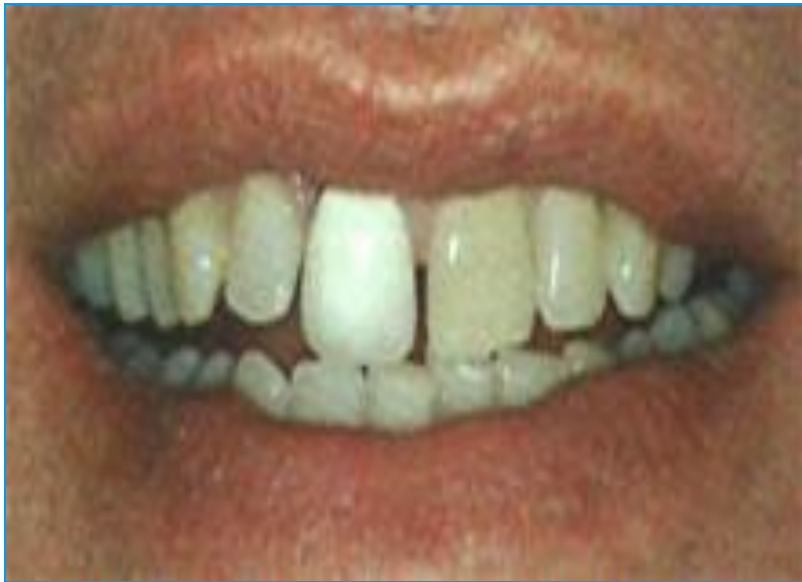3. A provisional restoration should maintain proper contacts with the adjacent and opposing teeth to prevent supraeruption and horizontal movement (drifting).



4. A provisional restoration should have enough strength and retention to withstand the forces to which it is subjected without fracture or coming off the tooth. In addition, it should remain intact during its removal so that it can be reused again-if necessary-.

5. A provisional restoration should provide esthetic, phonetic, and function.



Types of provisional restoration:

- 1. Preformed temporary crowns.**
- 2. Customized temporary restorations (chair side temporary restorations).**
- 3. Laboratory-made temporary restorations.**

1. Preformed temporary crowns:

Generally, preformed temporary crowns consist of a shell of plastic or metal that could be cemented directly on the prepared tooth following adjustment, or after its lining with a resin material. They could be used for single or multiple preparations.


Types of preformed temporary crowns:

- A. Metal temporary crowns.
- B. Plastic temporary crowns.
- C. Celluloid crown forms.

A. Metal temporary crowns:

Metal temporary crowns are mainly indicated for use in the posterior teeth. They are made of stainless steel, nickel-chromium, or aluminum. The most commonly used type is aluminum temporary crowns, which are of two types:

- 1. Non-anatomical or flat-topped cylindrical temporary crowns.**
- 2. Anatomical or morphological aluminum temporary crowns.**



Clinical Procedure

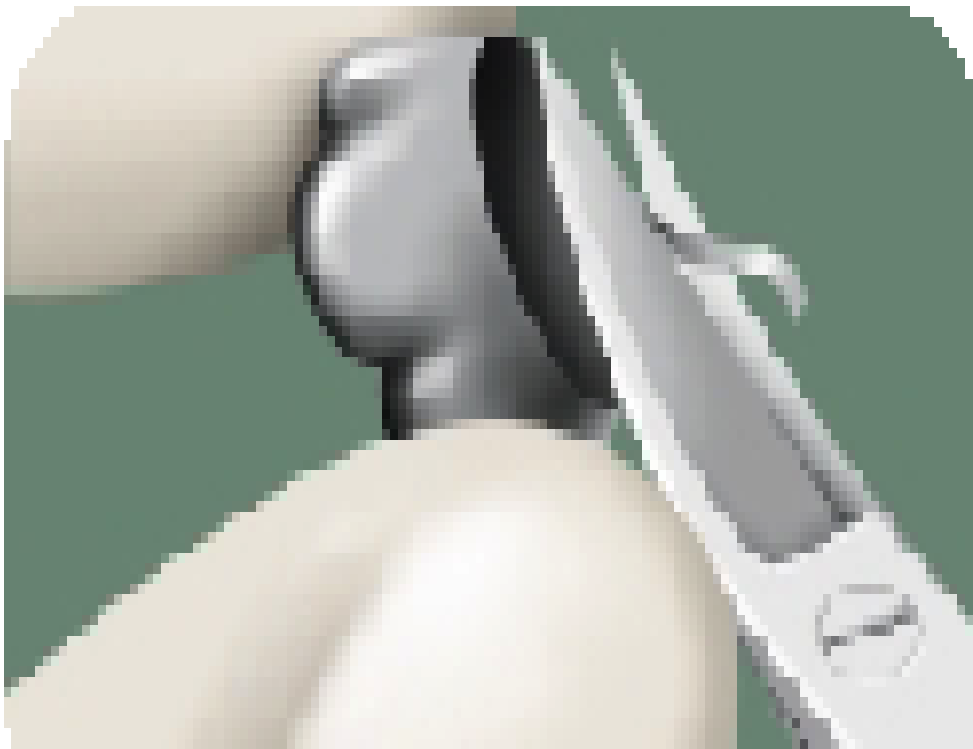
Clinical Procedure

1. Select the proper size and shape of the temporary crown according to the prepared tooth.



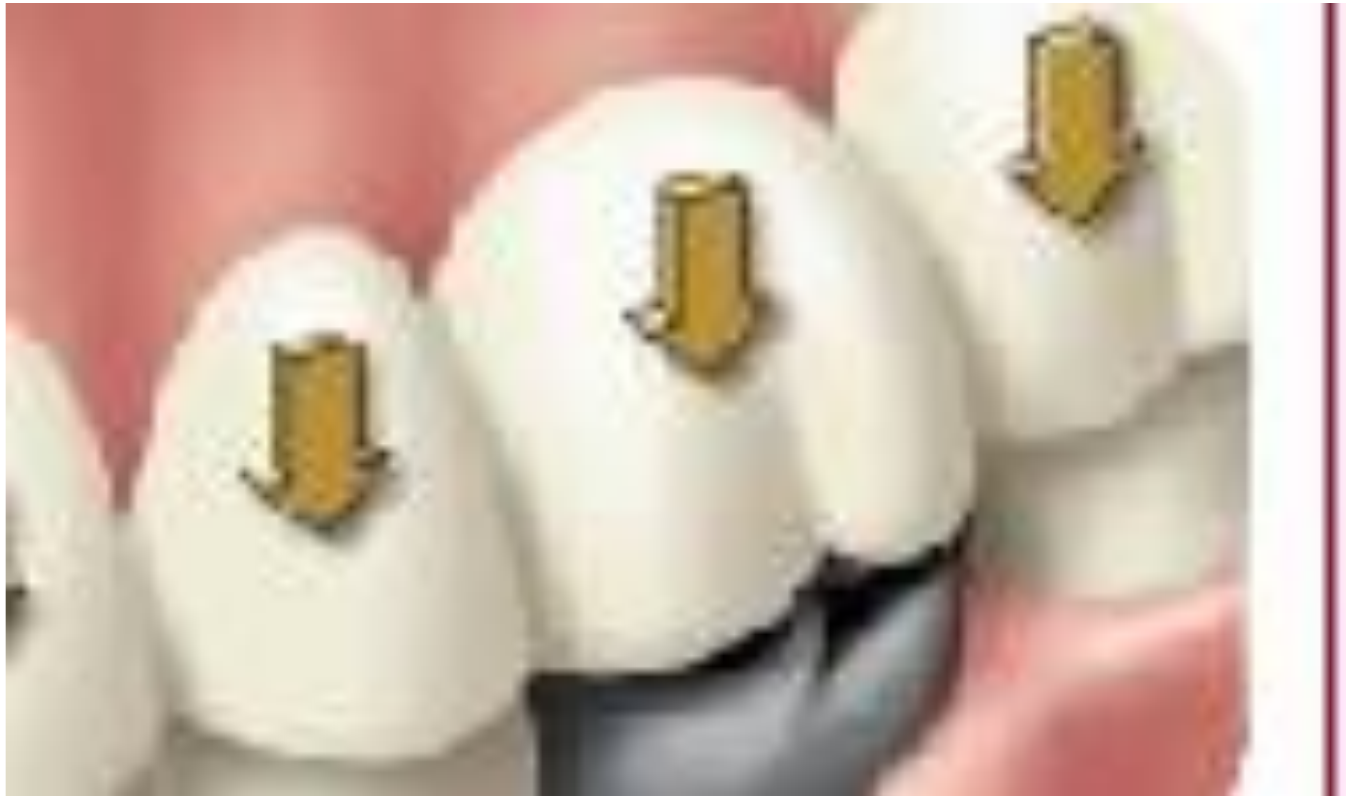Clinical Procedure

2. Trim the cervical margin of the temporary crown using a scissor to conform to the gingival margin of the preparation (finishing line) and to accommodate the vertical height of the prepared tooth.



Clinical Procedure

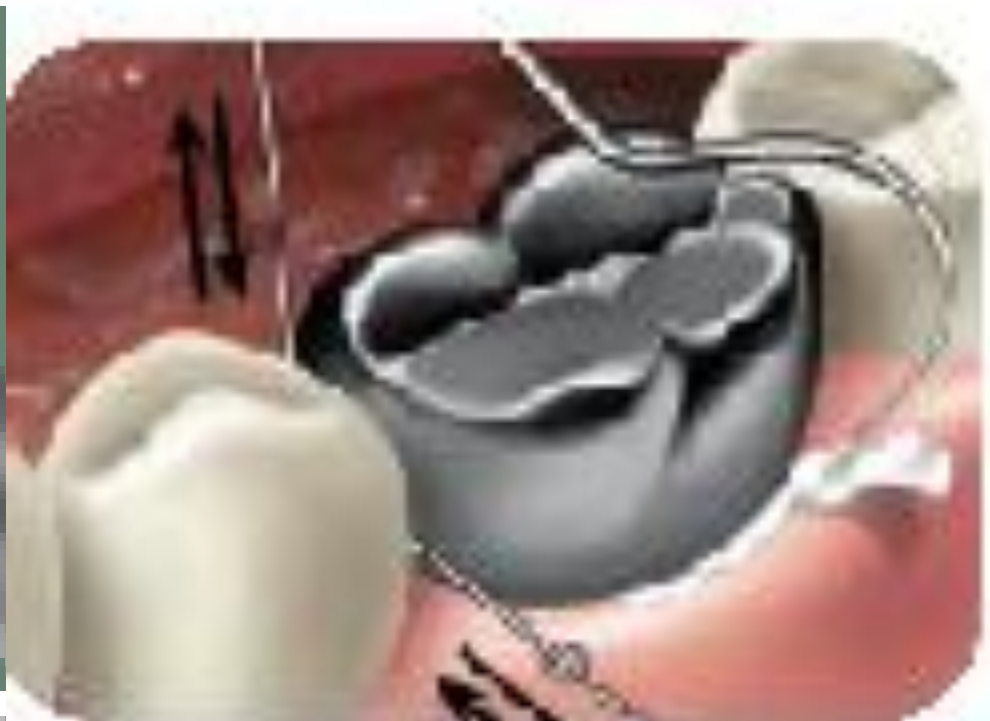
3. Seat the temporary crown on the prepared tooth and ask the patient to bite on it. Check the margins and the occlusion (centric and eccentric).



Clinical Procedure

4. Smooth the margins with a stone bur.

5. Cement the temporary crown on the prepared tooth using zinc oxide-eugenol cement.

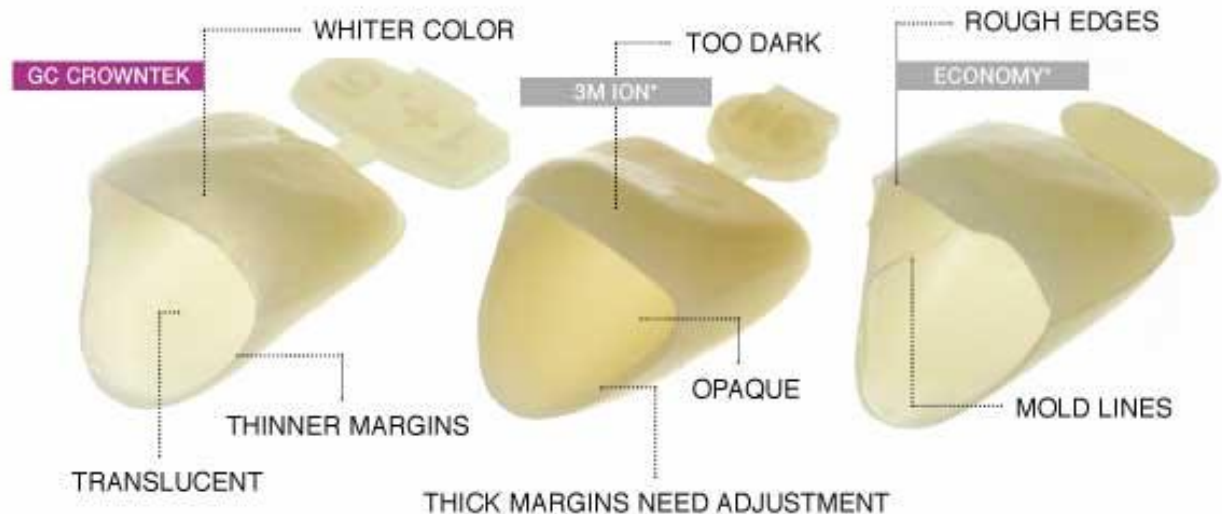

B. Plastic temporary crowns:

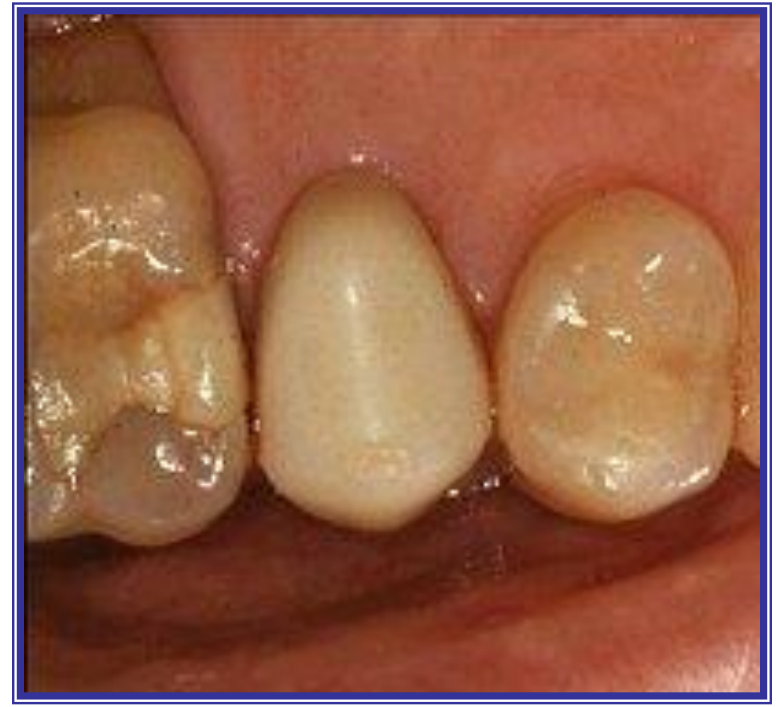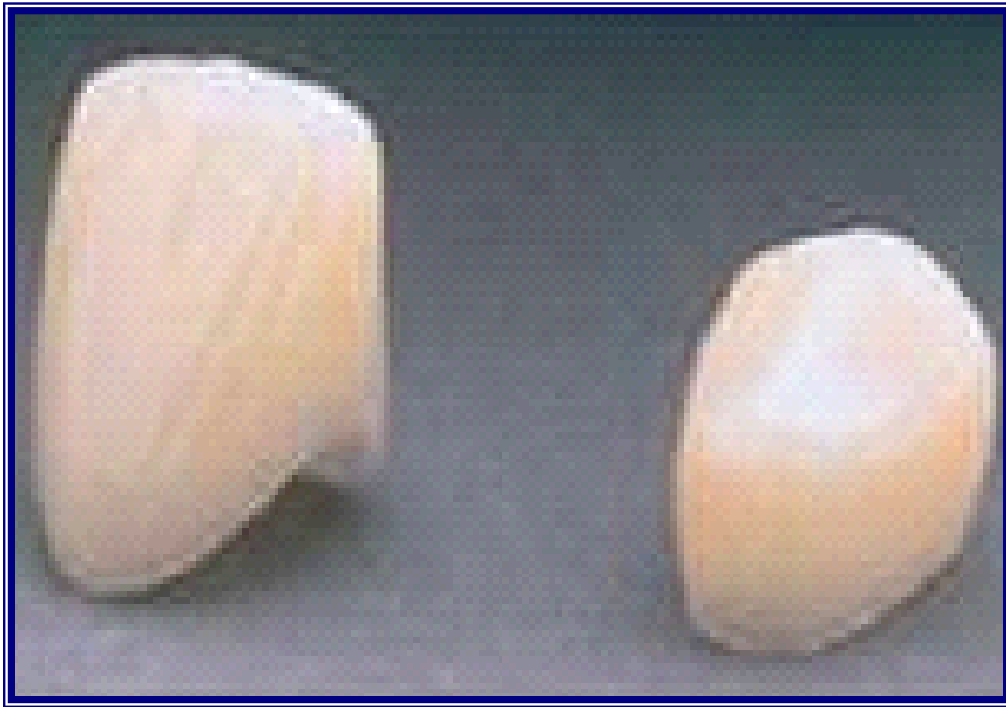Plastic temporary crowns are used mostly for the anterior teeth. The clinical procedure for the use of plastic temporary crown is nearly the same as that for metal temporary crown.

Types of plastic temporary crowns:

1. Polycarbonate temporary crowns: these are made from polycarbonate plastic combined with micro glass fibers. Preformed polycarbonate temporary crowns are available for the anterior and posterior teeth.

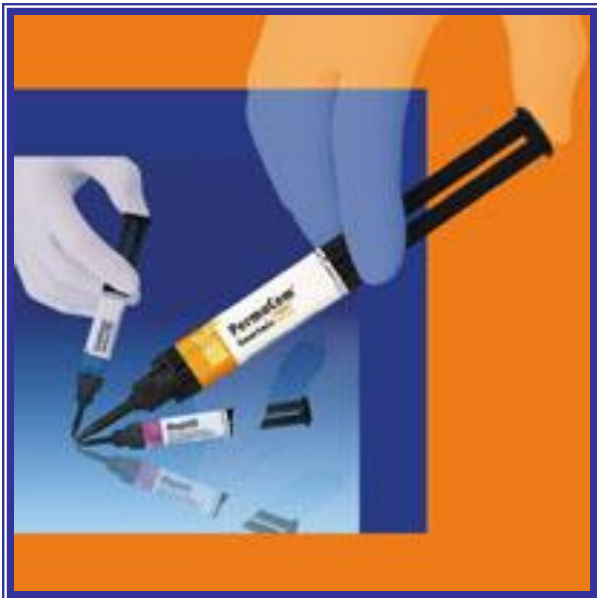

2. Acrylic temporary crowns: these are made from acrylic resin and are available in different sizes and colors. Preformed acrylic temporary crowns are used for the anterior teeth.

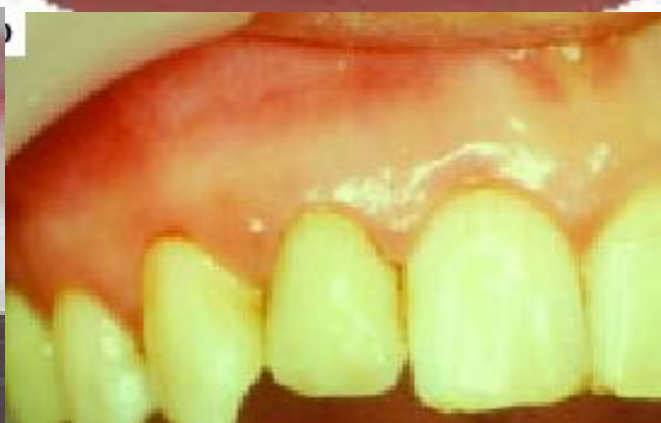
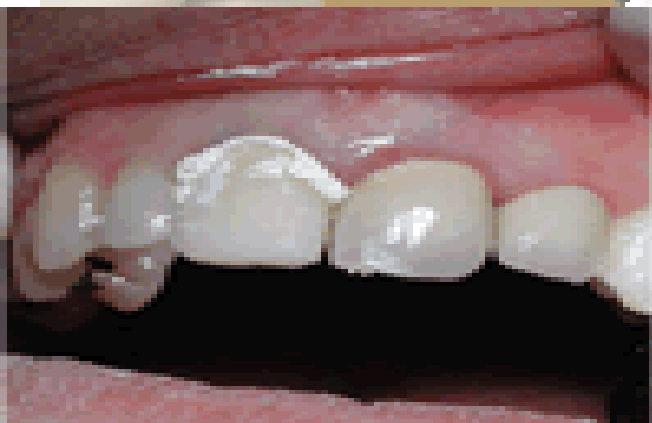
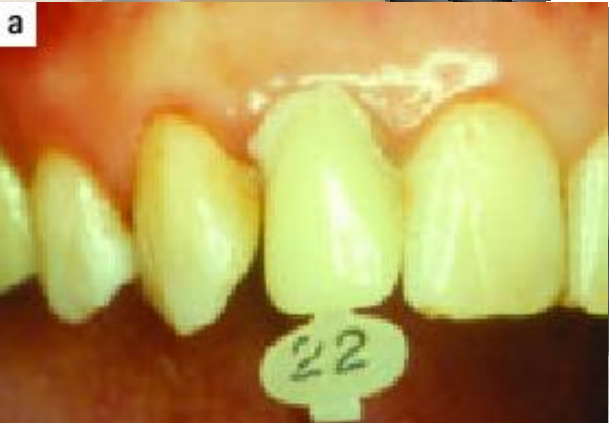
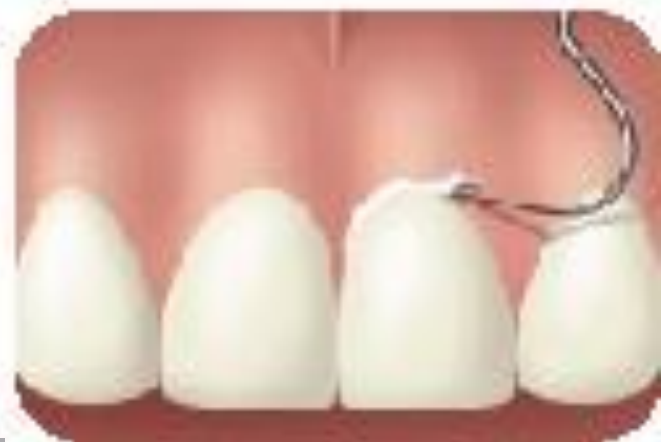
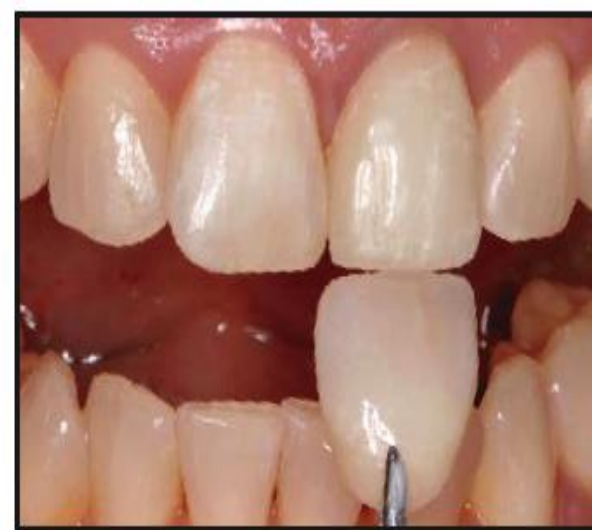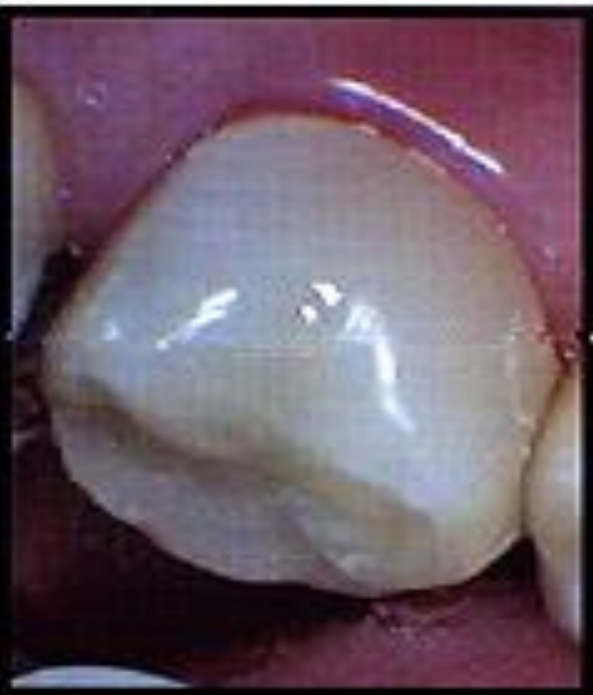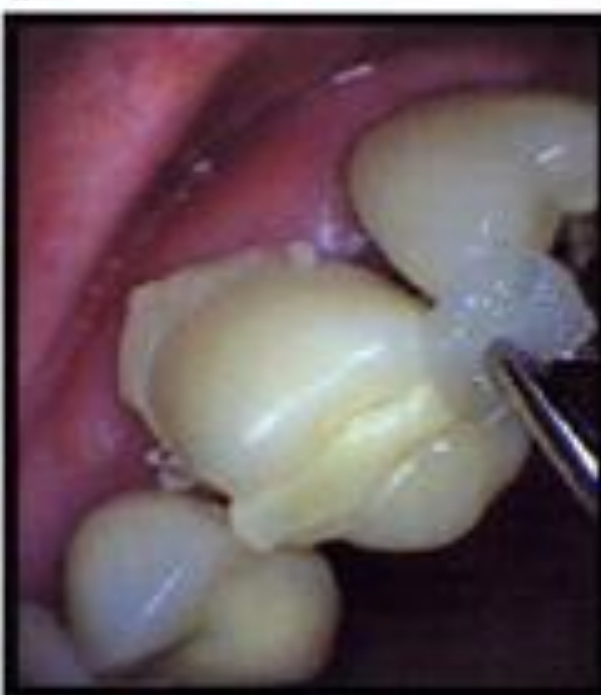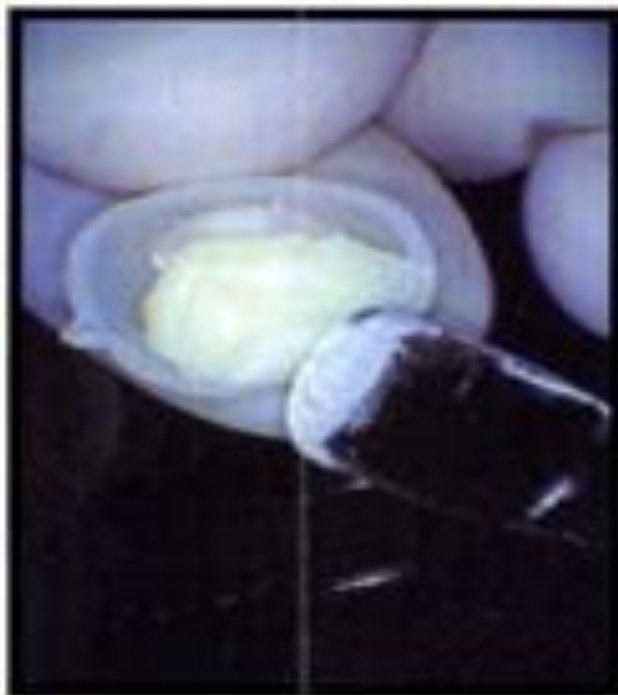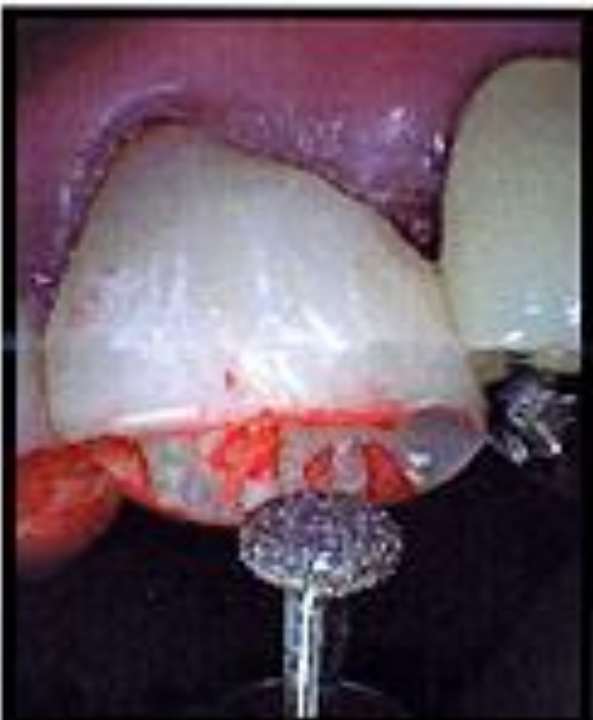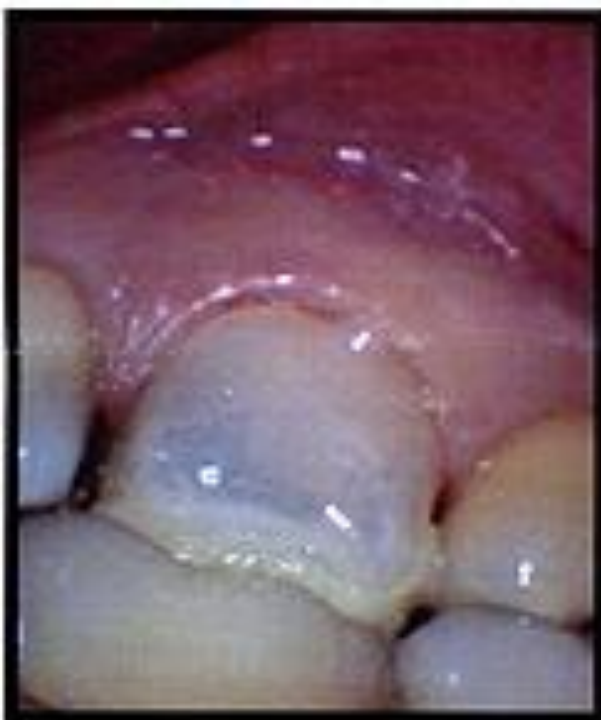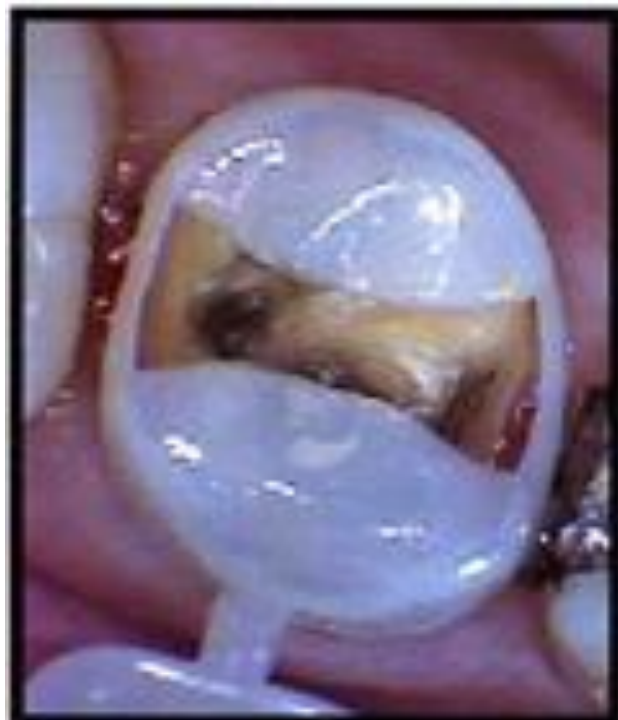In case we need to improve the fitness of the temporary crown or if there is no size which approximately fits the prepared tooth, we can reline the temporary crown with a resin material to improve its fitness after the selection of the most suitable size and shade (color) of the temporary crown and cutting its margin according to the finishing line of the prepared tooth.

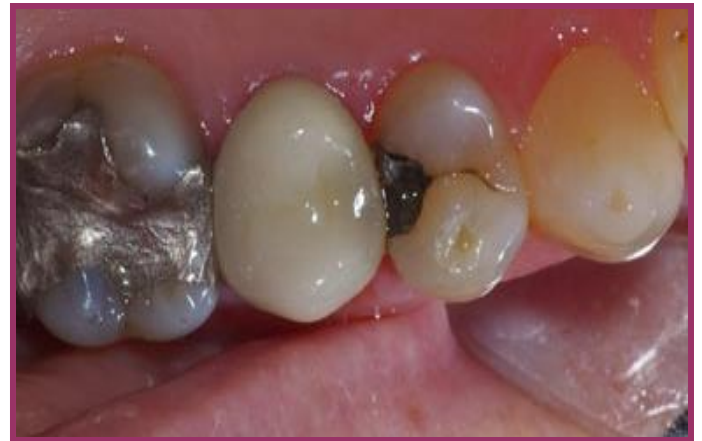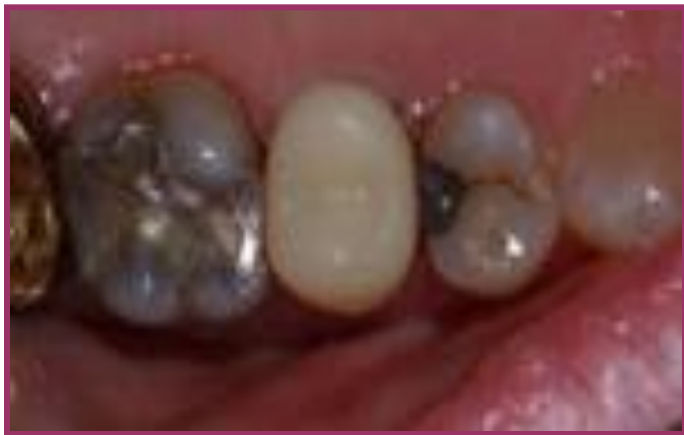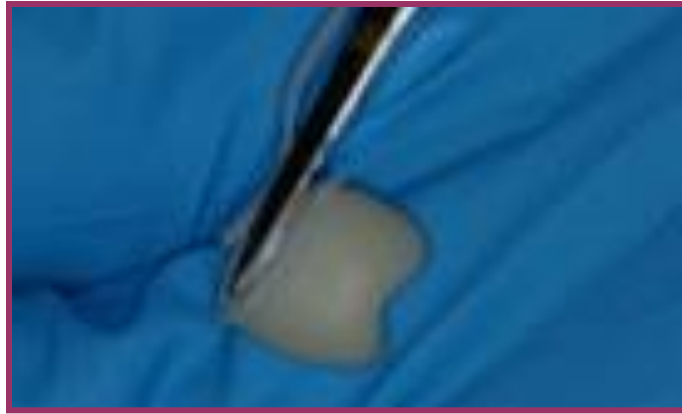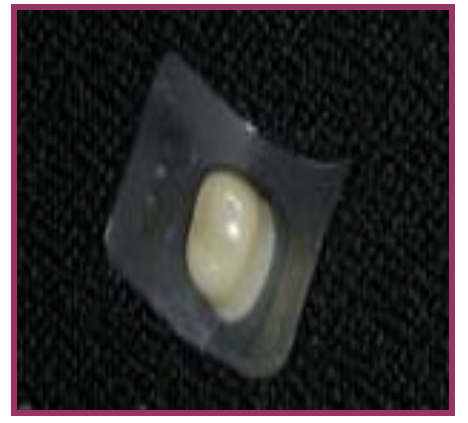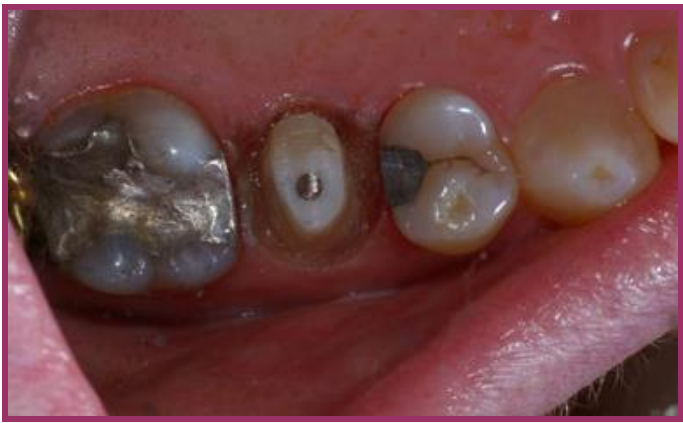The procedure of relining could be done either directly on the prepared tooth in a manner similar to that of celluloid temporary crown (will be discussed later) or could be done indirectly on a study cast of the prepared tooth.



Clinical Procedure







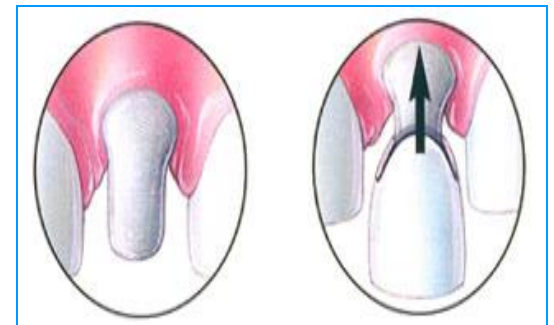
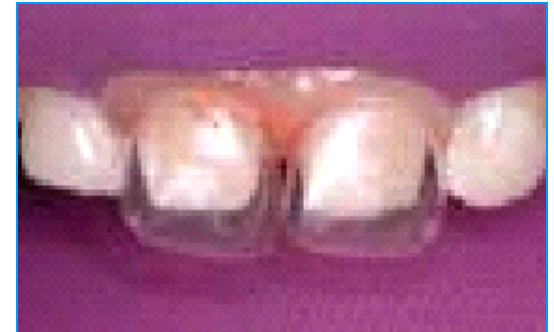C. Celluloid crown forms:

They are mainly used for the anterior teeth, but can be used for the posterior teeth also. They are made from a very thin translucent layer of cellulose acetate. They act as a mold for the construction of the temporary crown. They come in different sizes.

Clinical Procedure

Clinical procedure:

- 1. Coat the prepared tooth with vaseline to facilitate removal of the temporary crown.**
- 2. Select the proper size and shape of the celluloid crown.**
- 3. Make two holes in the corners of the temporary crown to provide an escape way for the excess material.**
- 4. Cut the gingival margin of the crown to accommodate that of the prepared tooth.**
- 5. Fill the celluloid crown with a provisional crown material (acrylic resin or composite resin) of the same shade of the tooth and seat it over the prepared tooth until setting.**



If acrylic resin is used as a provisional material, the celluloid crown should be removed at its semi-plastic stage so that the polymerization reaction of the acrylic resin will occur outside the mouth to prevent pulpal irritation since the polymerization reaction of the acrylic resin is exothermic.

6. Take the crown out and remove the excess material. Then place it again on the prepared tooth and check the occlusion, contact with the adjacent teeth, fitness, and extension.

2. Customized temporary crown and bridge :

The fabrication of customized temporary crowns requires the construction of a mold of the patient's teeth before their preparation. This may be obtained from any type of elastic impression material, into which resin polymer material (acrylic or composite) is placed and the mold is held either directly on the prepared tooth (or teeth) or indirectly against a cast of the patient's teeth.

Indications of customized temporary restoration:

- 1. Coverage of multiple individual crown preparations.**
- 2. Coverage of a single tooth preparation which is usually large or of a special design. i.e., when a preformed temporary crown is not fit to the tooth.**
- 3. Abutment preparations for fixed partial denture to construct a temporary bridge.**

Methods of construction of customized temporary restorations:

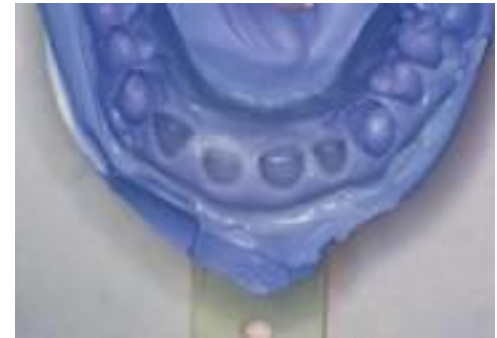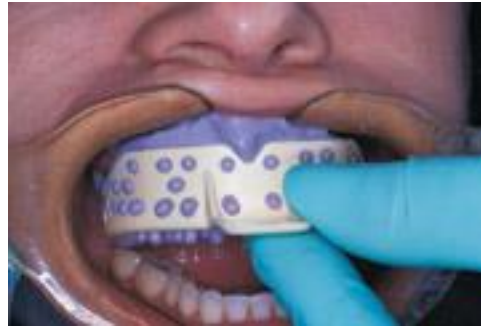- 1.** Impression method (the most commonly used method).
- 2.** Template method.
- 3.** Polycarbonate matrix method.
- 4.** Acrylic shell method.

Impression method:

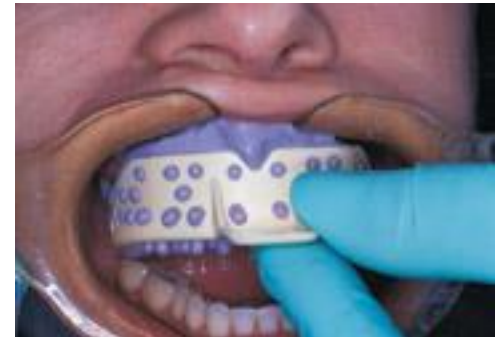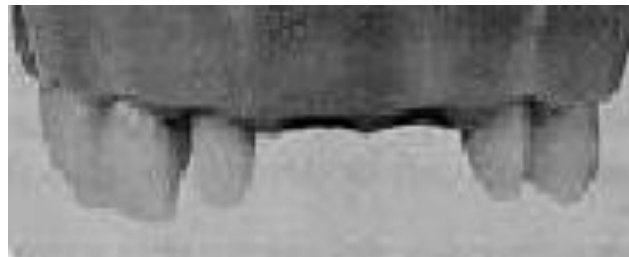- Indirect impression method.**
- Direct impression method.**

Indirect impression method (clinical procedure)


1. A preoperative over impression with alginate or silicone impression material is made from the patient's teeth or from a study model and carefully stored until completing tooth preparation (over impression).



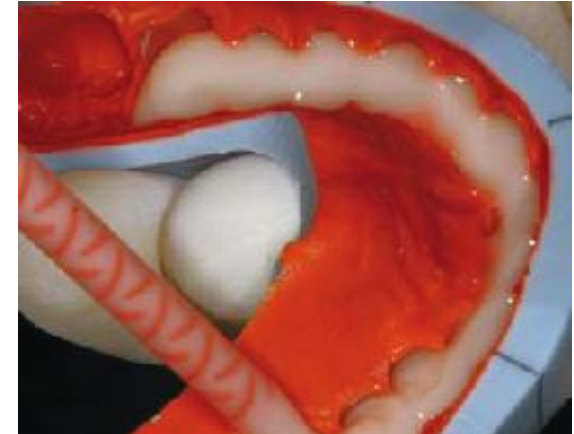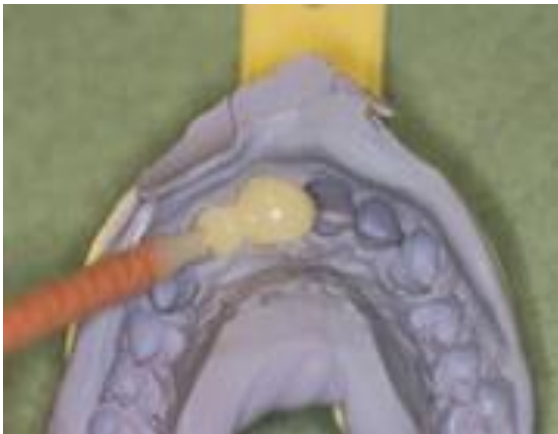2. After completing the preparation of teeth, another alginate impression was then taken and poured with fast-setting plaster or stone. After setting of the plaster or stone, the cast is separated from the impression.



3. Coat the prepared tooth (or teeth) on the cast with a separating medium (such as petroleum jelly).



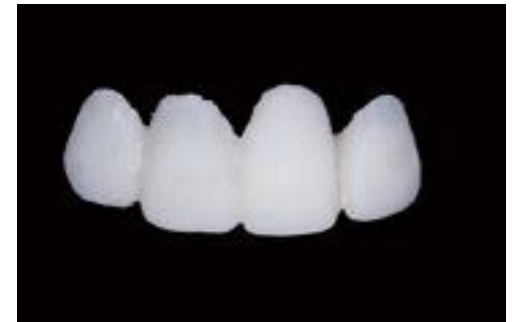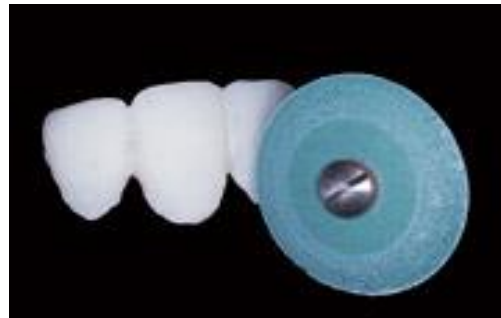4. Mix tooth colored acrylic resin according to the manufacturer's instructions and place the mixed acrylic in the over impression at the area of tooth preparation only.



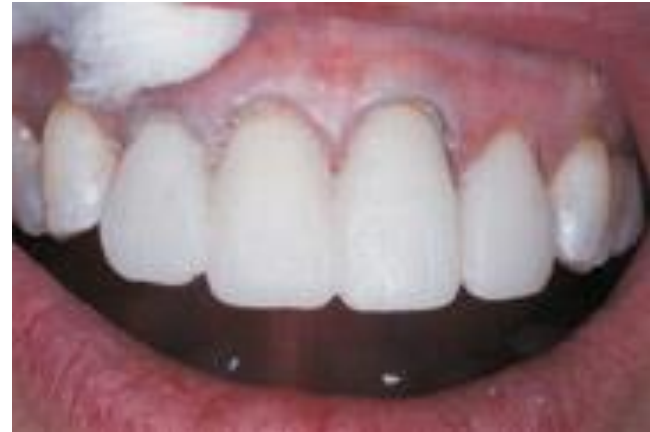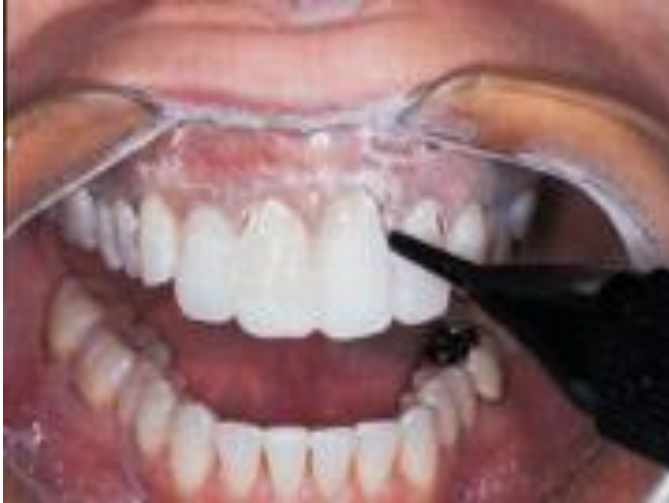5. Seat the cast into the over impression in an upright position and maintain constant pressure until the acrylic resin sets completely. It is important to note that the cast is correctly seated in the over impression.

6. After complete polymerization of the acrylic resin, separate the cast from the over impression. The formed crown (or bridge) is then removed from the prepared tooth (or teeth) in the cast.

7. Trim any excess material from the formed crown (or bridge). Then the crown (or bridge) is seated on the prepared tooth (or teeth) inside the patient's mouth. Check the occlusion and remove any premature contact in centric and eccentric occlusion.



8. Cement the temporary crown on the prepared tooth using zinc oxide-eugenol cement.



Clinical procedure of the direct impression method:

The clinical procedure of the direct impression method is the same as that of the indirect method except that it is done directly inside the patient's mouth. In this method, we need a preoperative over impression; there is no need to have a study cast. Prepare the tooth (or teeth), mix the acrylic resin, place it in the over impression in the area of tooth preparation, and seat the over impression inside the patient's mouth. Then follow the same steps that are used in the indirect method.

Advantages of the indirect method over the direct method:

- 1. There is no direct contact of the free monomer of the acrylic with the prepared tooth or gingival tissue which might cause tissue irritation or allergic reaction.**
- 2. The indirect method avoids subjecting the prepared tooth to the heat of polymerization of the acrylic resin since the polymerization reaction of the acrylic resin is exothermic.**
- 3. The indirect method saves the clinician's chair time.**

3. Laboratory-made temporary restorations.

A preoperative impression is made, and we prepare the tooth on the cast, and temporary crown or bridge is done. Relining by resin or composite material was done if the restoration has poor fitness. This technique also known as indirect direct technique.

Temporary restoration for a tooth prepared to receive a post crown:

It is often difficult to fabricate a temporary crown for a tooth that has been prepared to receive a post crown because there is so little tooth structure supragingivally that can not give support to the temporary crown, so in such a case we need intracanal retentive means to give retention to the temporary crown.

A piece of stainless steel wire could be used as an intracanal retentive means. The wire should be adapted to the prepared root canal and should extend coronally at least 4 mm. i.e., 4 mm of the wire should extend supragingivally outside the canal prior to the construction of the temporary crown. After that, a temporary crown could be constructed and the stainless steel wire will be part of the temporary crown.

Cementation of the temporary restoration:

Zinc oxide-eugenol cement is the most commonly used cement for temporary crowns and bridges. This cement promote healing and allows easy removal of the temporary restoration.

