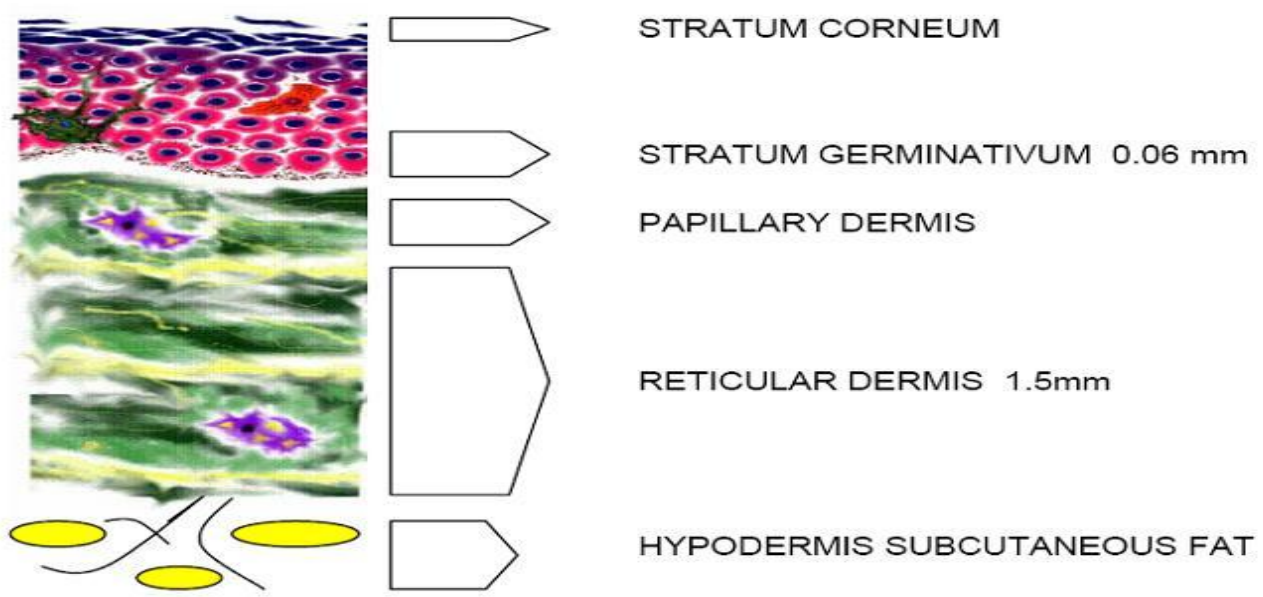
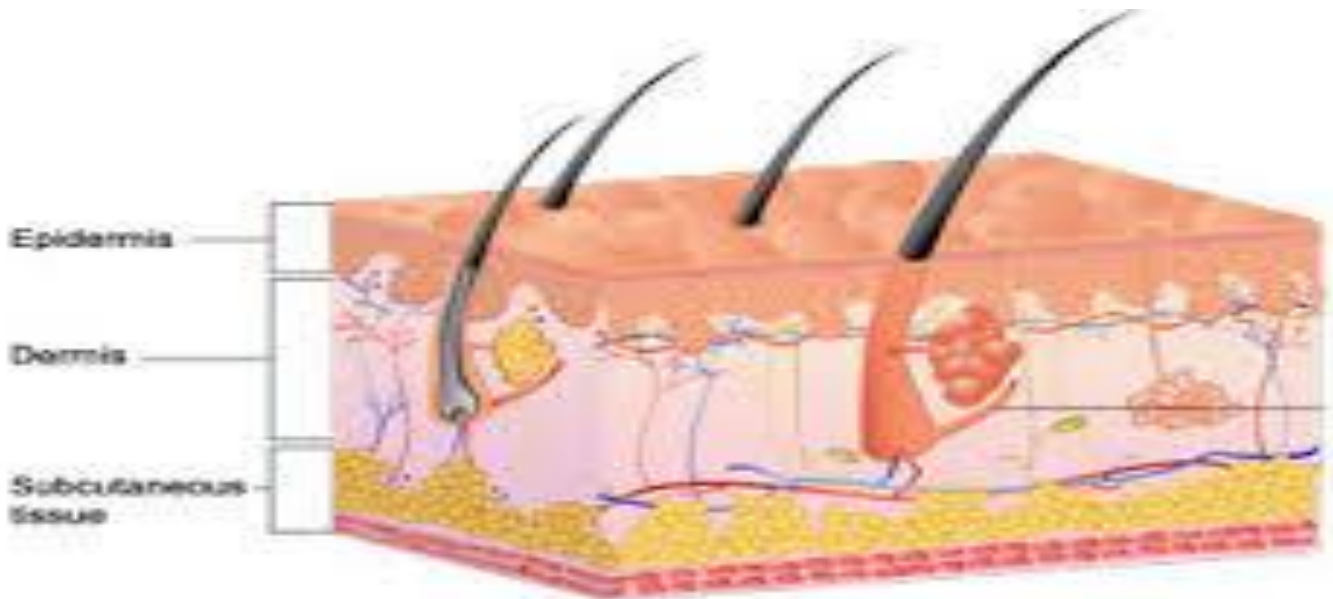

MORPHOLOGY OF SKIN LESIONS

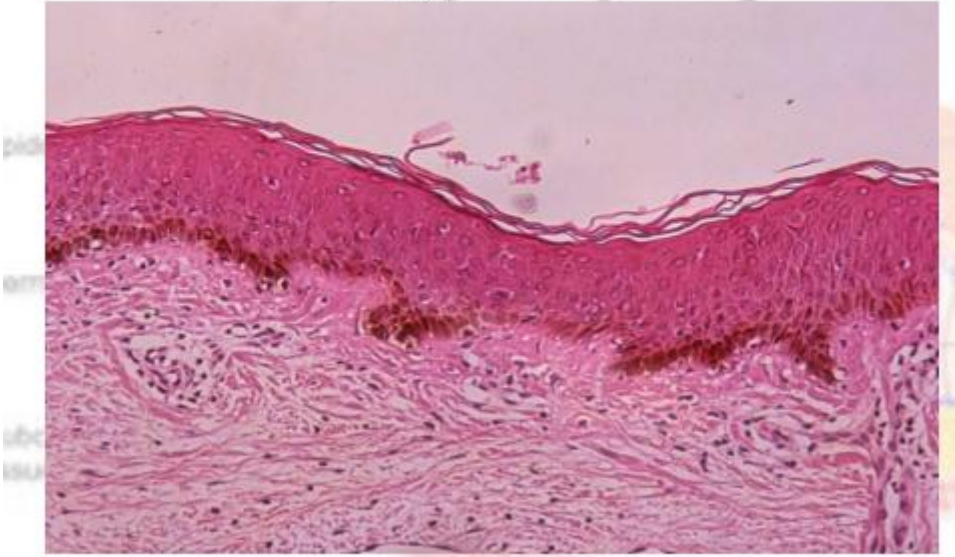
Structure of the skin:

The skin compose of three layers:

- Epidermis (cells only)
- Dermis (connective tissue , blood vessels and nerves)
- Subcutaneous layer : fatty layer protect the body from heat and mechanical trauma



Histology of The Skin



Primary lesions :(original lesions) produced by the disease it self

- Macule,
- patch
- Papule,
- plaque,
- nodule,
- tumor
- cyst
- Wheals
- Vesicle
- Bullae
- Pustule

B. Secondary Lesions:the primary lesions continue to develop or may be regress, or if it is subjected to trauma , or due to the effect of itching , infection , or to the effect of treatment

:

- Scales
- Crusts
- Ulcers
- Excoriations
- Erosions
- Fissures
- Scars-hypertrophic scars
- Keloid
- Lichenification

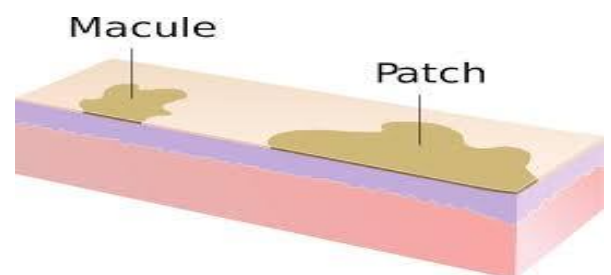
Primary lesions

Mucule: spot

- Circumscribed discoloration of the skin
- without elevation or depression
- of less than 1 cm in diameter
- Has a flat surface
- E.g. vitiligo , freckles

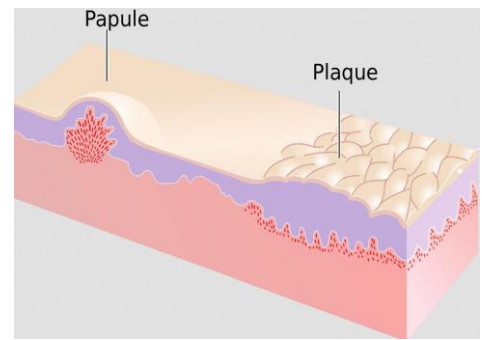
Patch

- If the discoloration is larger than 1 cm.



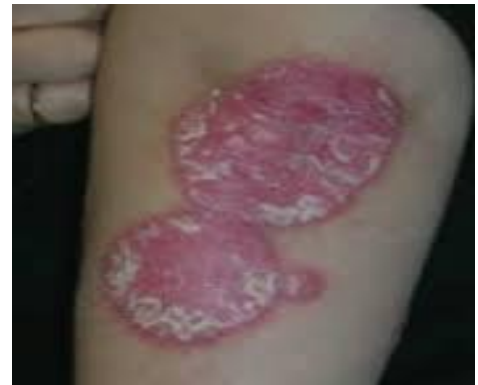Papule- (Latin Paula, “Pimple”)

- Are circumscribed,
- solid elevations of skin
- of less than 1 cm in the skin .
- E.G. Acne , warts



Plaques: (French- Plaque- “Plate”)

- if it is more than 1 cm or confluences of papules



Nodules" small knot

Similar to papule but it has two elements :

1. Depth.
2. Elevation of the epidermis
 - e.g. : acne , leishmania

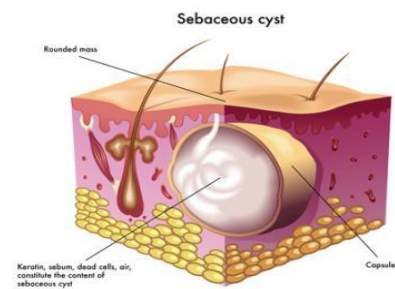
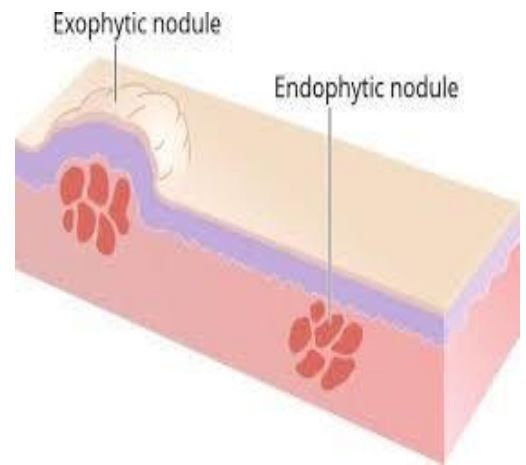
Tumors

- Soft or firm
- Freely movable or fixed masses
- of various sizes and shape.

“A tumor is an abnormal mass of tissue, the growth of which exceeds and un-coordinated with normal tissue and persists in the same excessive manner after cessation of stimulus which evoked the change”.

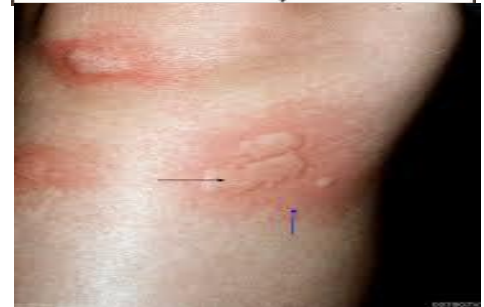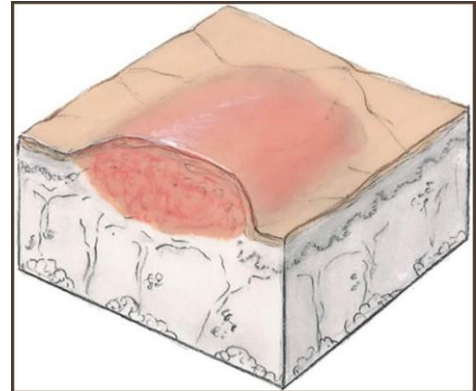
Cyst

a cyst is a cavity containing liquid or semi-solid material may be superficial or deep.

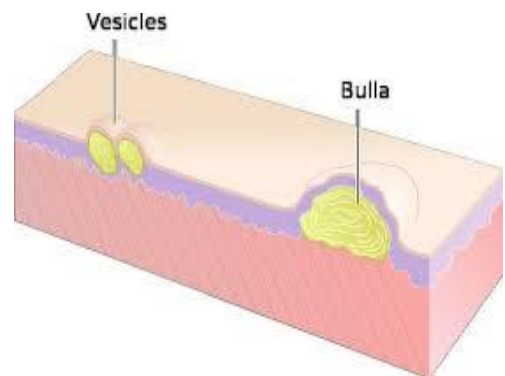


Wheals (Hives) wheals

- Circumscribed edematous papule with erythematous boarder and pale center, could be of various size .
- It is evanescent (transient) takes few hours and fade-away
- It is characteristic lesion of urticaria

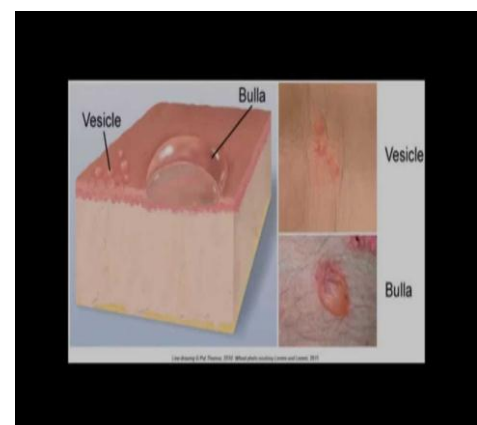


- **Vesicles** “Little bladder” :
- are circumscribed epidermal elevations
- less than 1 cm in size
- and containing **clear** fluid.



Bullae ” Bubble ”:

- are circumscribed or irregularly shaped cavity
- more than 1 cm in diameter
- containing **clear , serous or seropurulent fluid.**

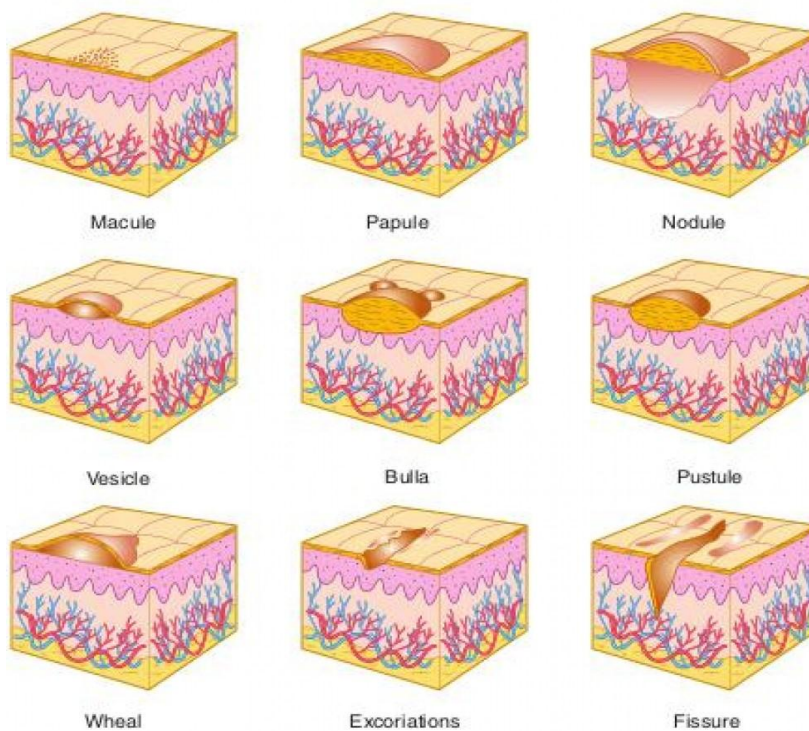
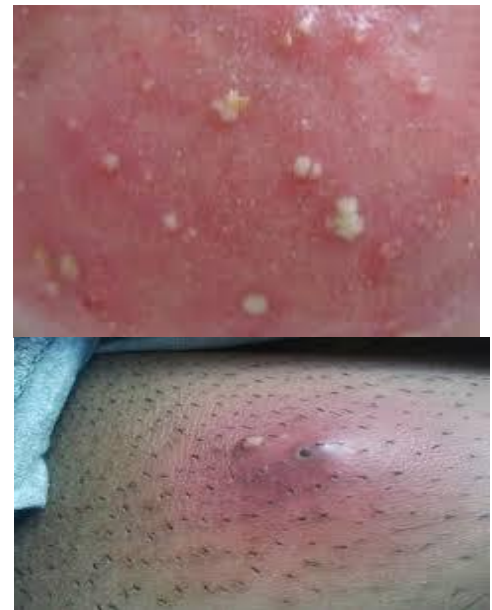

Pustule (Pustula-Pus):

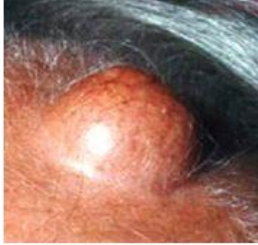- circumscribed accumulation of pus in the skin
- of less than 1 cm in diameter .

Abscess :

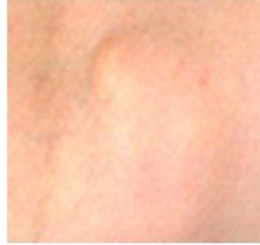- circumscribed accumulation of pus in the skin
- of larger than 1 cm in diameter



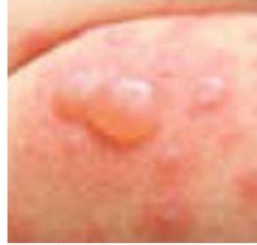Primary Skin Lesions



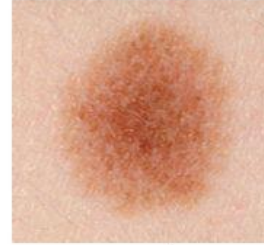nodule



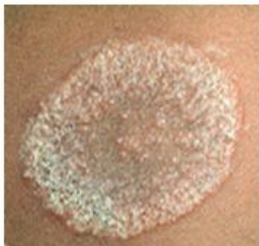cyst



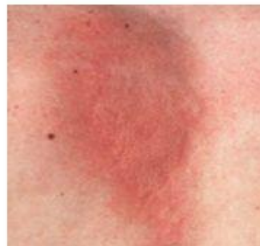bullae



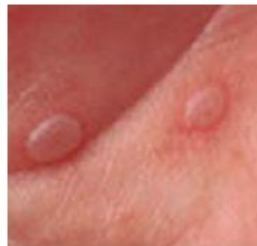macule



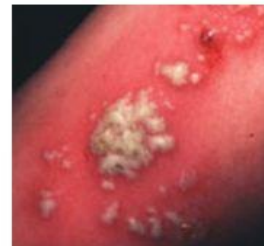plaque



wheal

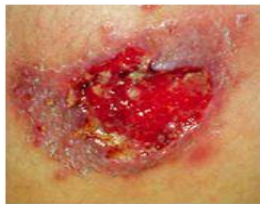

vesicle

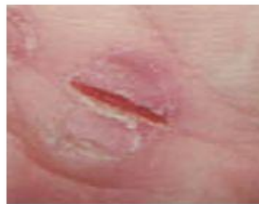

pustule

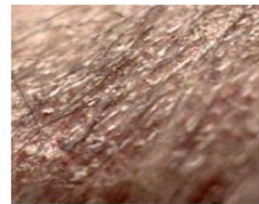Secondary Skin Lesions



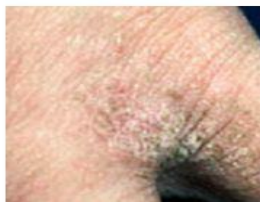ulcer



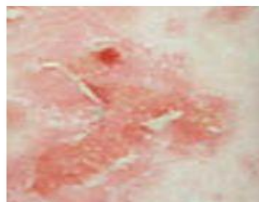
fissure



scale



lichenification



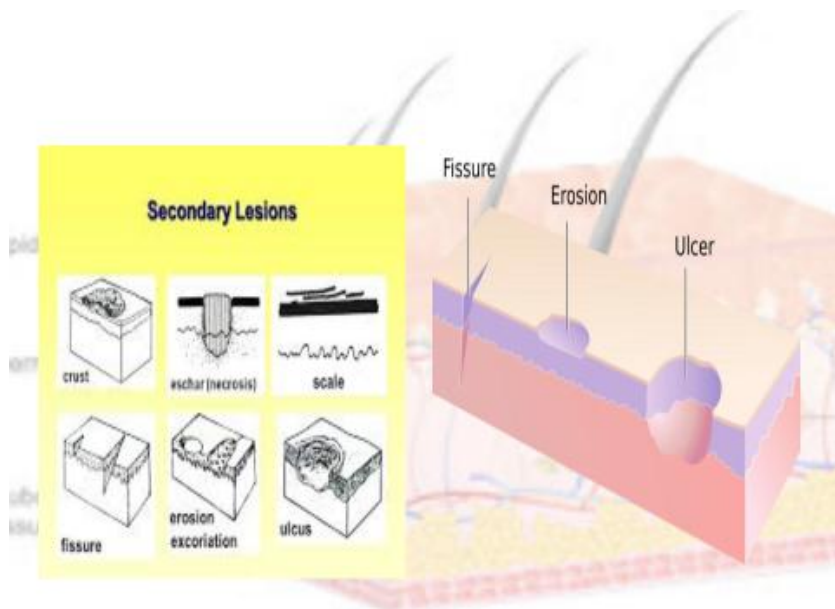
erosion



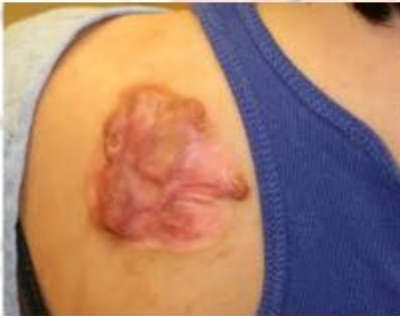atrophy

Secondary Lesions

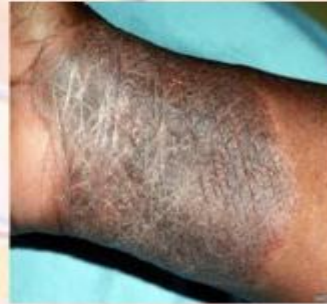- **Scales:** are sheets of dead keratinocyte accumulated together , dry or greasy laminated masses of keratin accumulated together before shedding
- **Excoriations** : an excoriation is a punctate or linear abrasion produced by mechanical means usually involving only the epidermis and rarely reaching the papillary layer of the dermis .
- **Erosions:** loss of all or portion of **epidermis alone**, heal *without scar* .
- **Fissures** : is a linear cleft or crack through the epidermis or rarely into the dermis caused by disease (eczema) or injury.
- **Ulcers** loss of **epidermis and part of the dermis**, heal *with scar* .
- **Crusts** are dried serum, pus or blood, usually mixed with epithelial and bacterial debris, on the surface of the skin .
- **Scars** accumulation of fibrous tissue in the dermis or deeper parts as a result of injury or disease, as a part of the normal healing process , scar may be **hypertrophic or atrophic**
- **Keloid** (claw like) is a firm, irregularly shaped, thickened, hypertrophic, fibrous, pink or red excrescence.
- **Lichenification** : thickening of the skin with increase skin marke and hyperpigmentation , as in chronic eczema



KELOID



LICHENIFICATION



Skin Lesion Guide

			
Bulla Circumscribed Collection Of Free Fluid > 1 Cm	Macule Circular Flat Discoloration < 1 Cm Brown, Blue, Red or Hypo Pigmented	Nodule Circular, Elevated, Solid Lesion > 1cm	Patch Circumscribed Flat Discoloration > 1cm
			
Papule Superficial Solid Elevated, < 0.5 Cm, Color Varies.	Plaque Superficial Elevated, Round Flat Topped Lesion > 1 Cm	Pustule Vesicle Containing Pus (Inflammatory Cells)	Vesicle Circular Collection Of Free Fluid, < 1 Cm
			
Wheal Edematous, Transitory Papule, May Last Few Hours	Scale Epidermal Thickening Consists Of Flakes Or Plaques of Compacted Desquamated Layers Of Stratum Corneum	Crust Dried Serum Or Exudate On Skin	Fissure Crack Or Split
			
Erosion Linear Erosion	Ulcer Loss Of Epidermis (Superficial); Part Or All Of The Epidermis Has Been Lost	Lichenification Thickening of the epidermis seen with exaggeration of normal skin lines	Scar Thickening, permanent fibrotic changes that occur on the skin following damage to the dermis

© 2009 Wound Care Education Institute - www.wci.net

