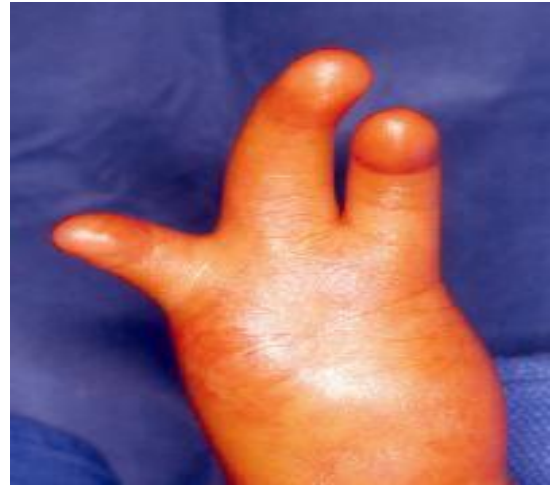

# Disorders of the hand

## Congenital anomalies

### Failure of formation

- ž Hand or digits

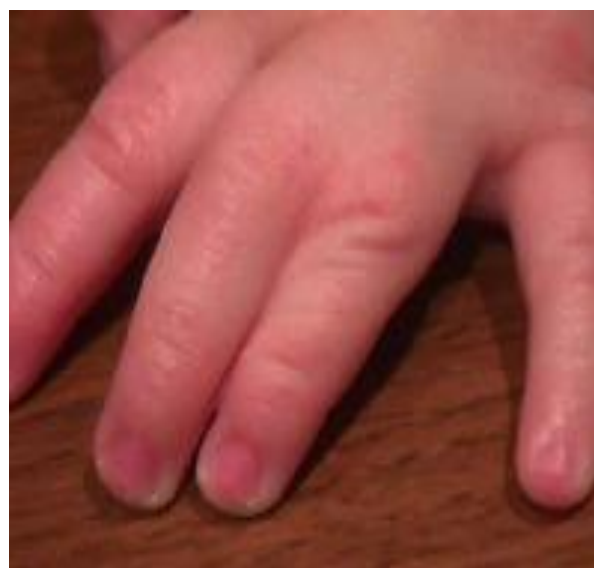
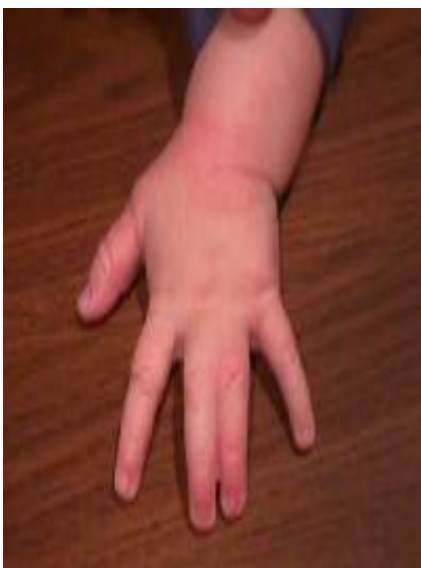
### Cleft hand

Failure of formation of the middle one or 3 rays

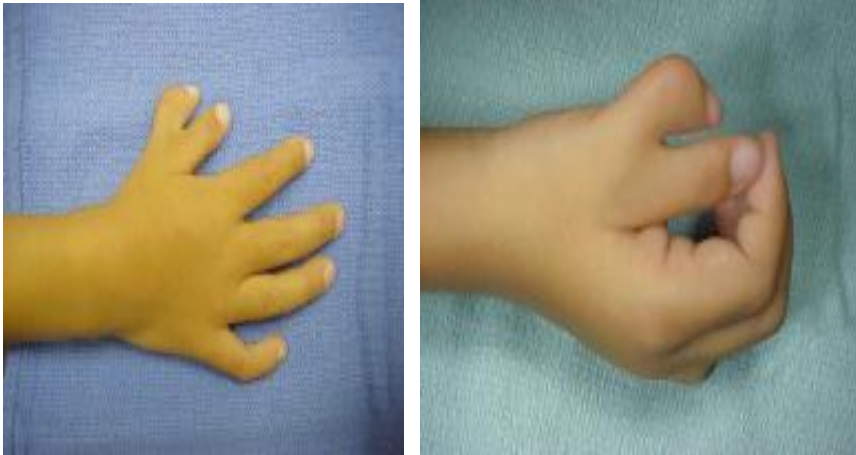## Syndactyly

- Commonest
- Fusion between 2 or > digits
- Rx : surgical separation at age of 1-2 yrs



## Polydactyly

- Duplication of digit
- Rx : excision + ligament reconstruction



## Camptodactyly

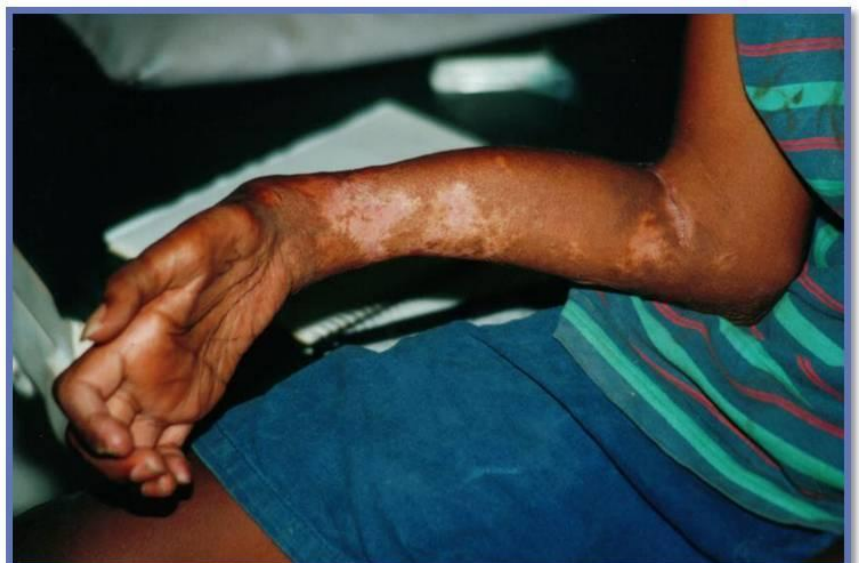Flexion contracture of PIPJ of little finger

## Hand incisions

- Do not cross skin crease
- If have to.....never at 90°
- 45°

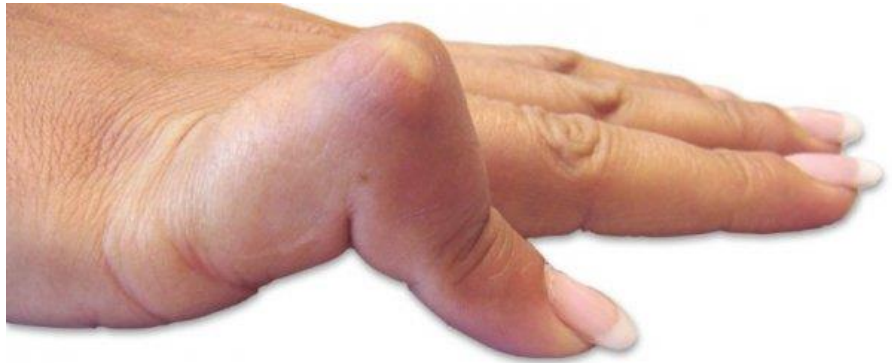## Volkmann`s contracture

- Due to compartment syndrome
- DDx : claw-hand deformity
- Rx : tendon lengthening



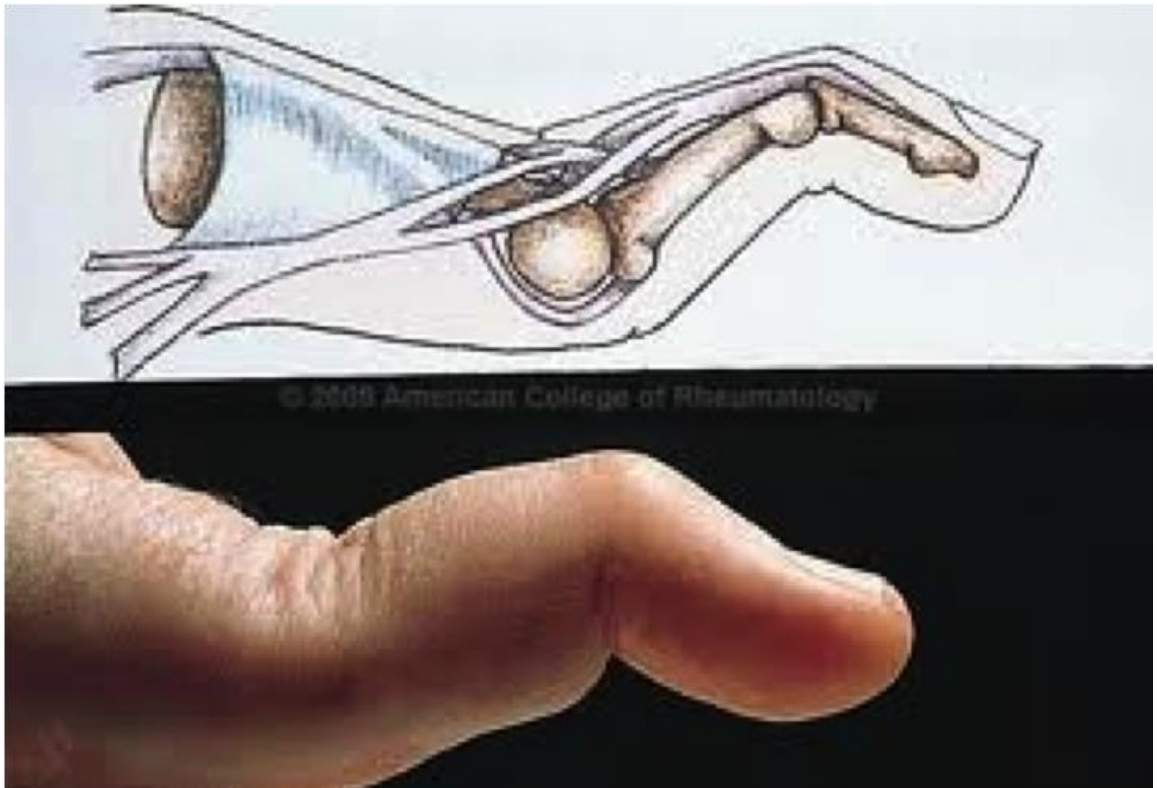
## Boutonnière deformity

- Due to rupture or stretching of central slip
- Trauma
- RA
- Rx : repair



## Swan-neck deformity

- Trauma
- RA
- Ligament laxity
- Mallet finger
- Paralysis of FDS



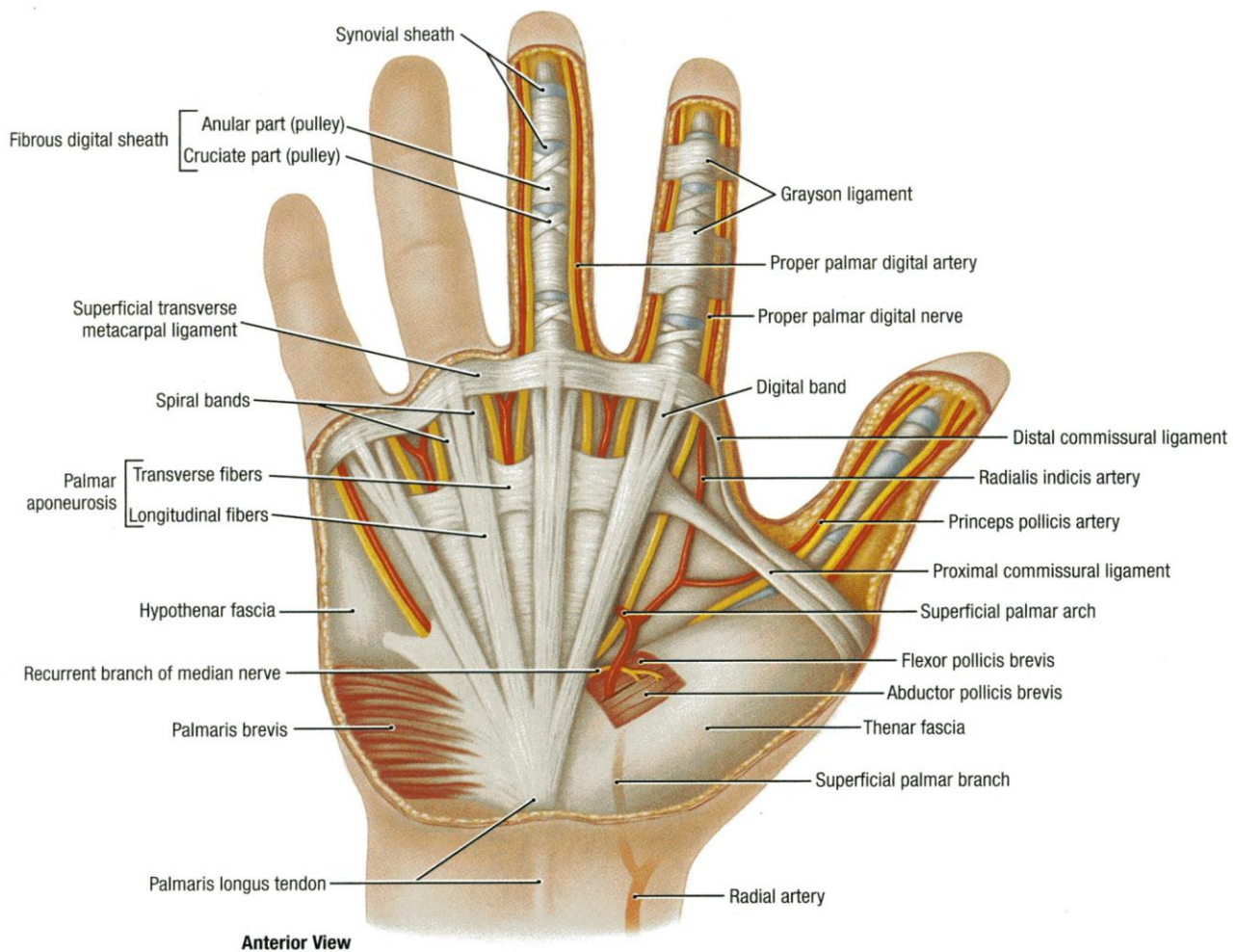
- Rx : splint
- surgery : partial release of central slip

## Trigger finger

- Due to stenosing tenosynovitis
- Local trauma
- RA
- DM
- Rx : local steroid
  - surgical release

## Dupuytren`s contracture

Pathology: proliferation of myofibroblasts in palmar aponeurosis



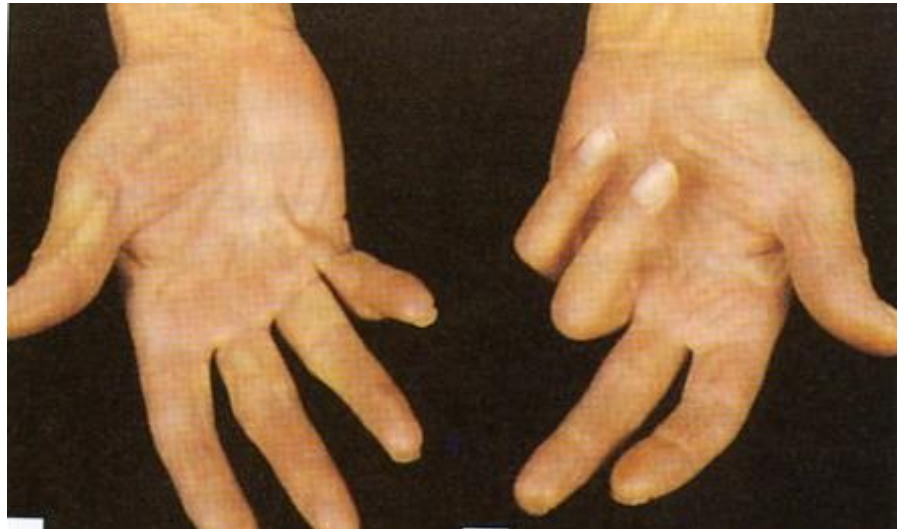## Associations

- Family hx
- Anglo-saxon
- DM
- Alcoholic cirrhosis
- Smoking



## C / F

- Middle - aged
- Male
- Nodular thickening of the palm
- Flexion contracture of the little and ring fingers



## Rx

- Surgical excision
- Recurrence is common

**Mubark A. Wilkins**