


- 
- Date 15/6/2020
  - Subject :histology
  - Lecture 2
  - Glandular Epithelial Tissue
  - First year
  - Time(2-3)h
  - Dr. Sabreen Saleem AL –Sayigh(Ph.D.)

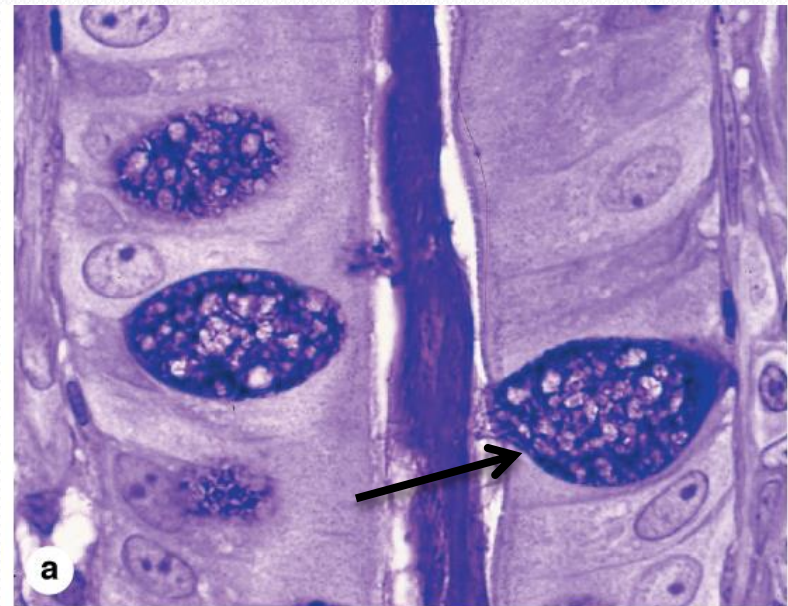
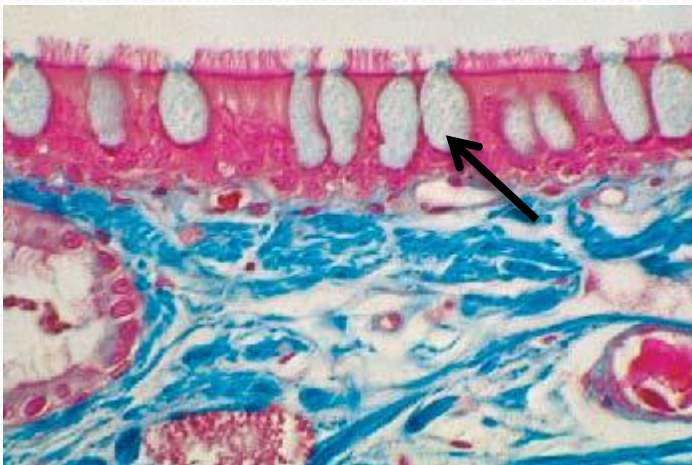
# Glandular Epithelia

- Glandular epithelia are formed by cells specialized to produce secretion. The molecules to be secreted are generally stored in the cells in small membrane-bound vesicles called **secretory granules**
- Glandular epithelial cells may synthesize, store, and secrete proteins (eg, pancreas), lipids (eg, adrenal, sebaceous glands), or complexes of carbohydrates and proteins (eg, salivary glands). The mammary glands secrete all three substances. Less common are the cells of glands that have low synthesizing activity (eg, sweat glands) and that secrete mostly substances transferred from the blood to the lumen of the gland.



# Types of Glandular Epithelia

- The epithelia that form the glands of the body can be classified according to various criteria. Unicellular glands consist of isolated glandular cells, and multicellular glands are composed of clusters of cells. An example of a unicellular gland is the **goblet cell** (of the lining of the small intestine) or of the respiratory tract

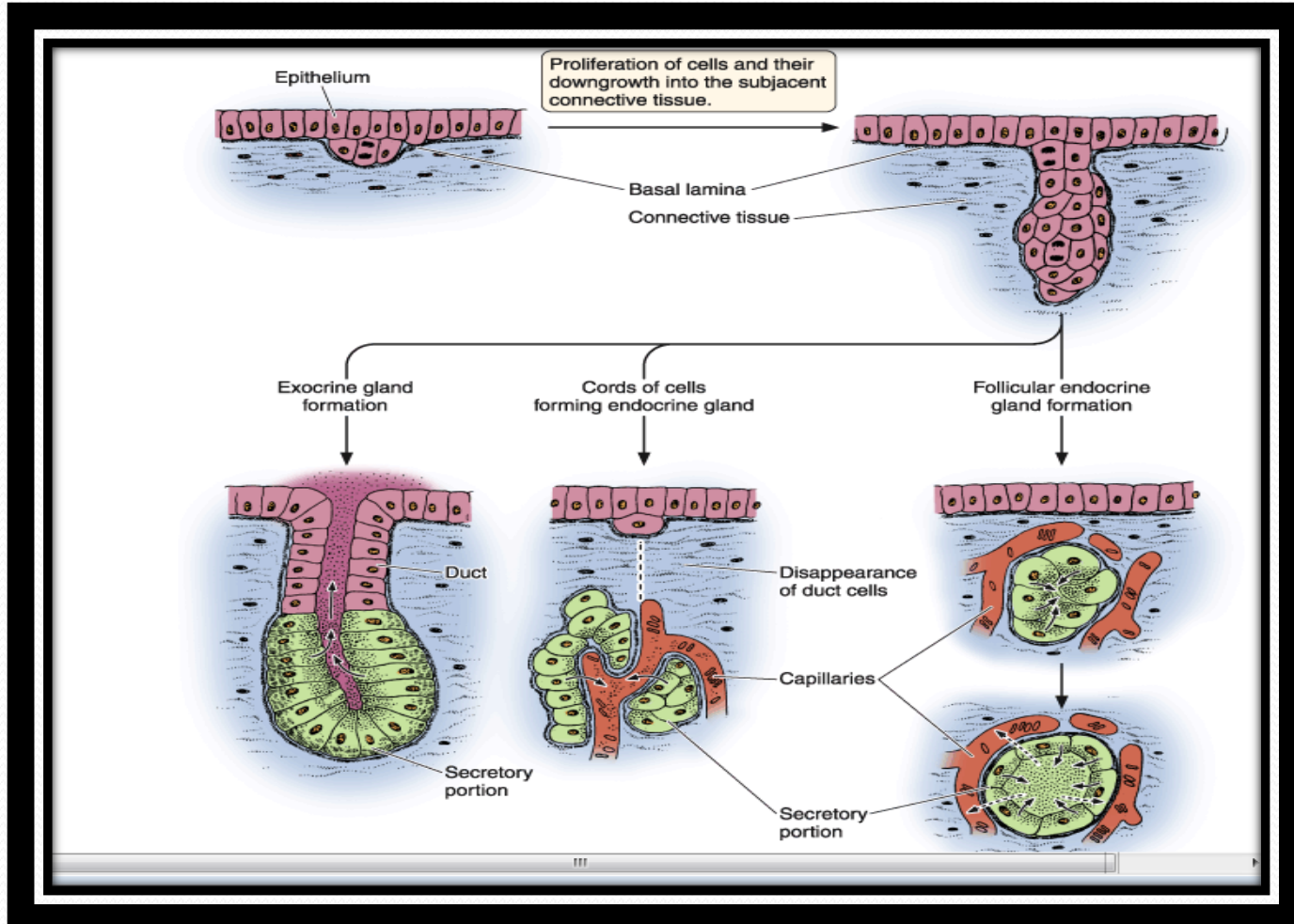


# Types of Glandular Epithelia

- . Glands develop during fetal life from covering epithelia by means of cell proliferation and invasion of the subjacent connective tissue, followed by further differentiation ,**Exocrine** glands retain their connection with the surface epithelium from which they originated. This connection is transformed into tubular ducts lined with epithelial cells through which the glandular secretions pass to reach the surface. **Endocrine** glands are glands whose connection with the surface is lost during development. These glands are therefore ductless, and their secretions are picked up and transported to their site of action by the bloodstream rather than by a duct system (as show figure 3).

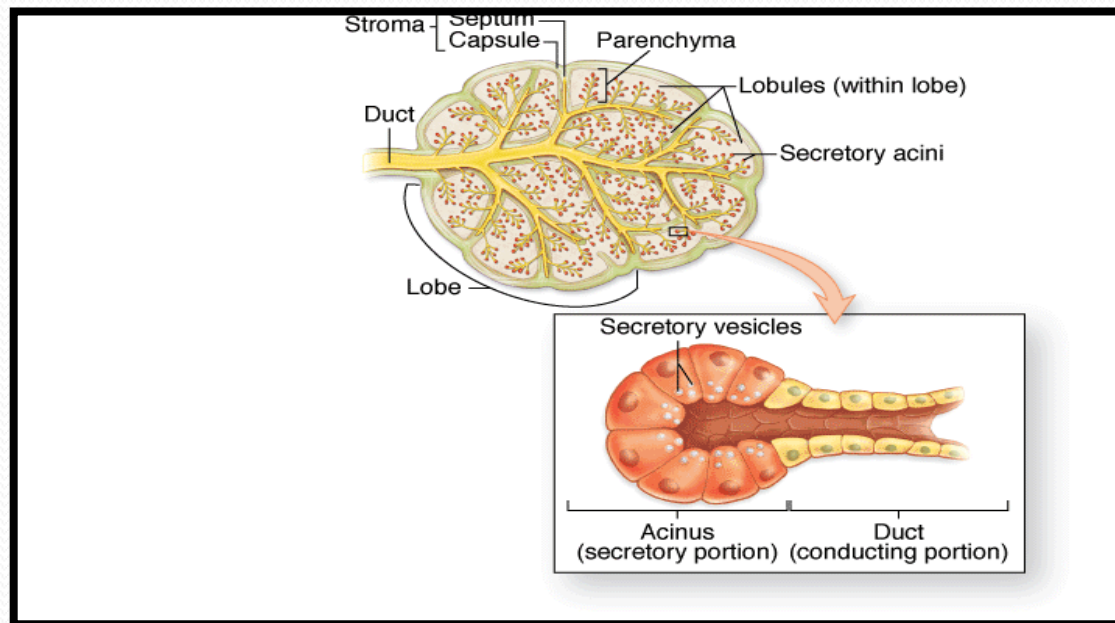


# Types of Glandular Epithelia



# Types of Glandular Epithelia

- Multicellular glands, whether exocrine or endocrine, also have connective tissue in a surrounding capsule and in septa that divide the gland into lobules. These lobules then subdivide, and in this way the connective tissue separates and binds the glandular components together as figure.



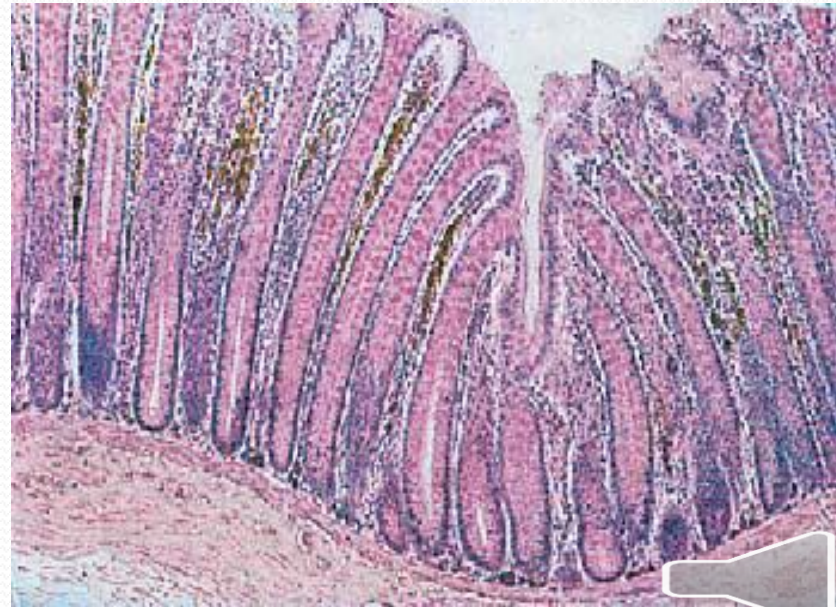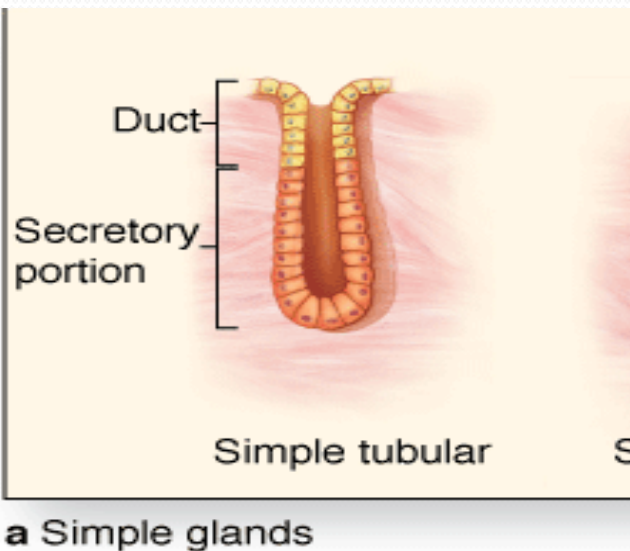
## Types of Glandular Epithelia

- Two types of endocrine glands can be recognized based on the arrangement of their cells. The endocrine cells may form anastomosing cords interspersed between dilated blood capillaries (eg, adrenal gland, parathyroid, anterior lobe of the pituitary) or they may arrange themselves as vesicles or follicles filled with non cellular material (eg, the thyroid gland).
- Exocrine glands have a **secretory portion**, which contains the cells responsible for the secretory process, and **ducts**, which transport the secretions. **Simple glands** have only one un branched duct, whereas **compound glands** have ducts that branch repeatedly.



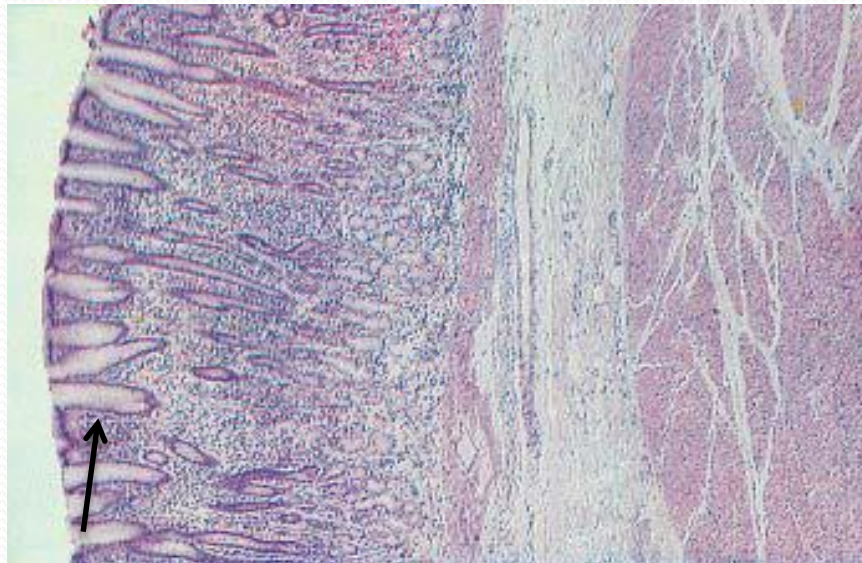
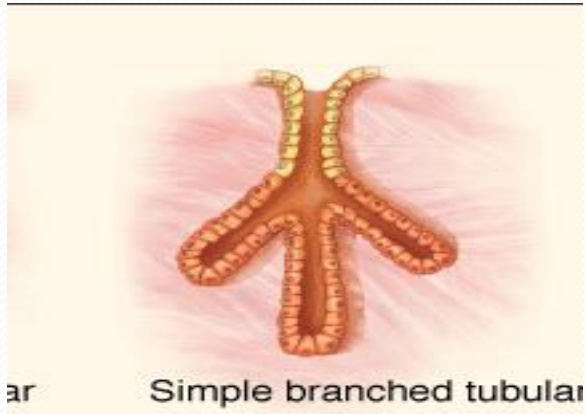
# Classification and Type of multicellular gland

**1**-Simple tubular glands have only one unbranched duct that connects directly to surface( e.g intestinal gland ).

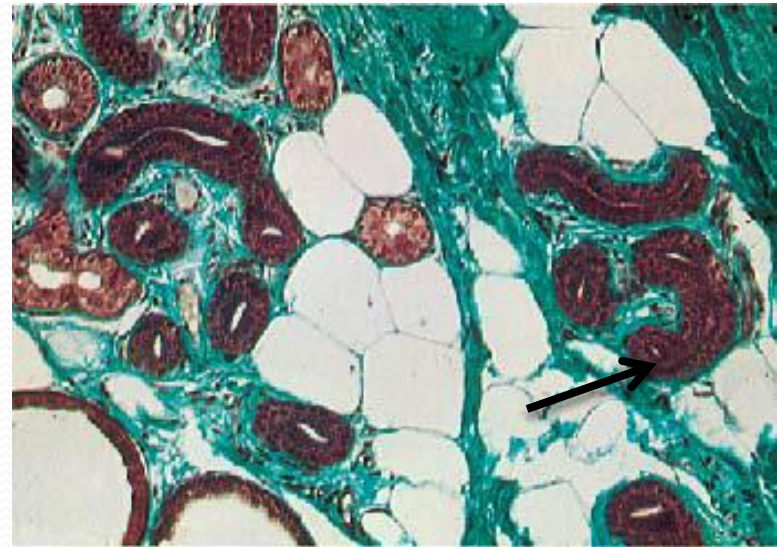
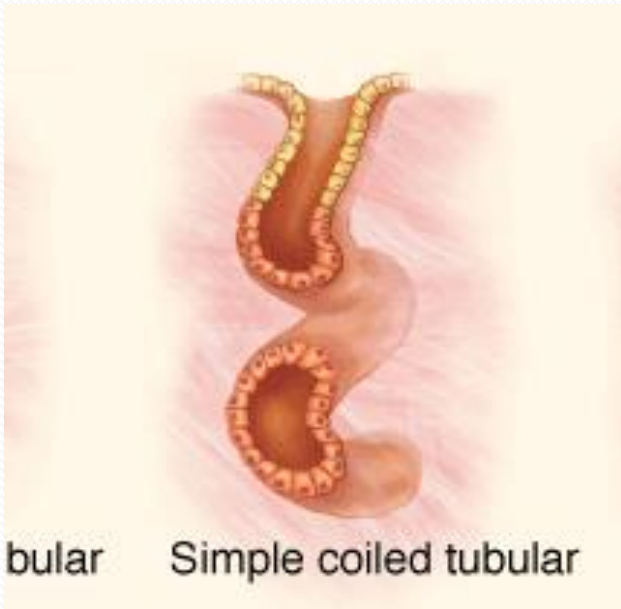




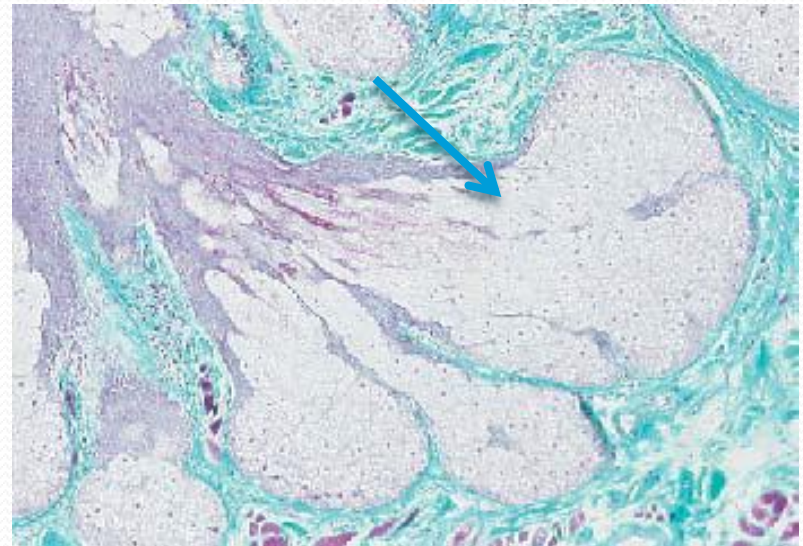
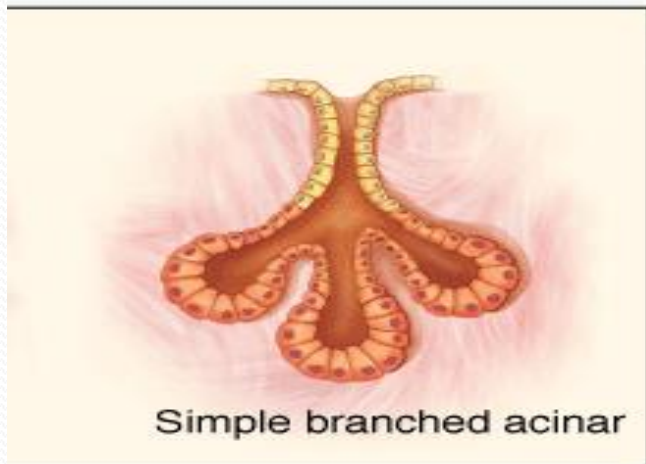
2-Simple branched tubular glands : tubular gland whose secretory units branch ( e.g, fundic gland of stomach ).



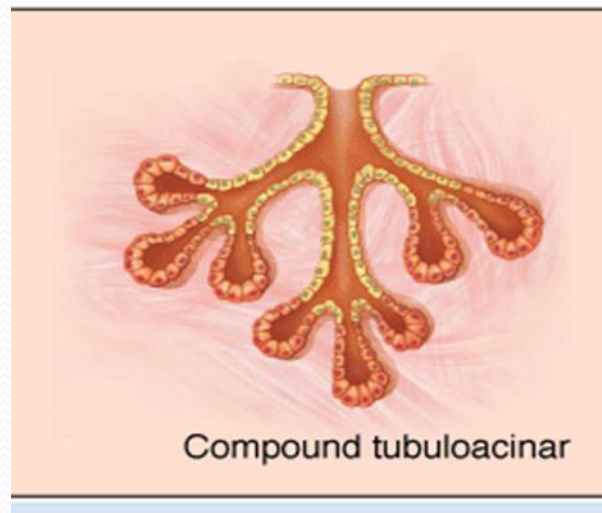
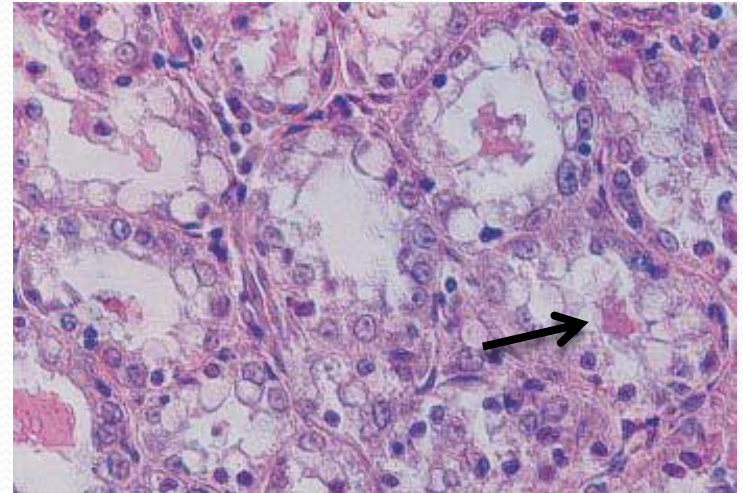
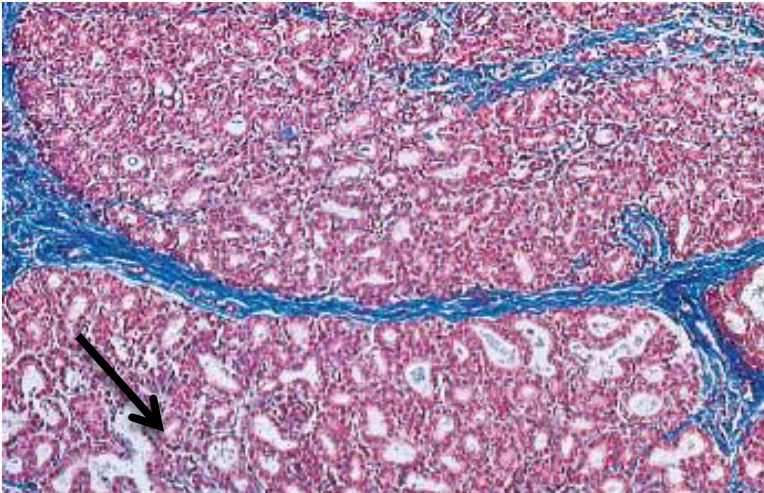
3-Simple coiled tubular glands: Long un branched duct , the secretory unit is long coiled tube (e.g., sweat gland).



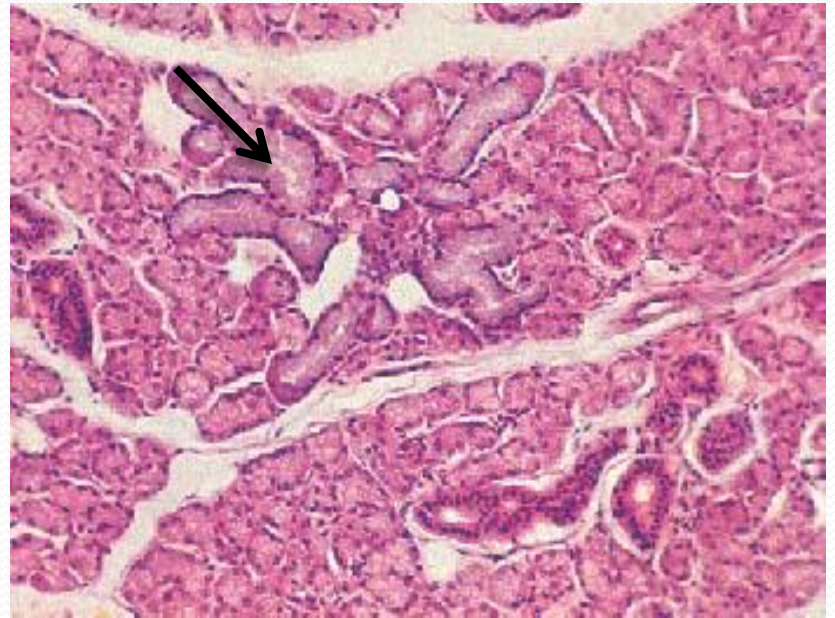
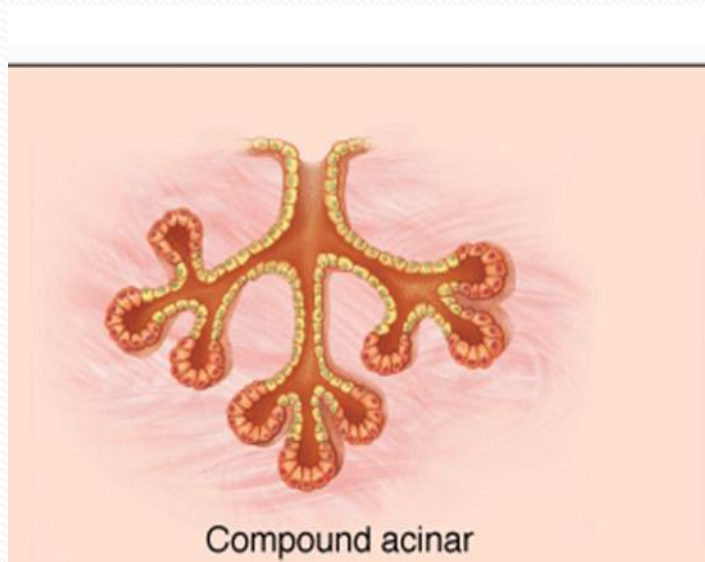
4-Simple branched acinar glands( alveolar). Secretory units are branched and open into a single duct(e.g. sebaceous gland).



5- Compound tubulacinar(alveolar):Branching ducts with both tubular and acinar secretory units (e.g., submaxillary salivary gland).

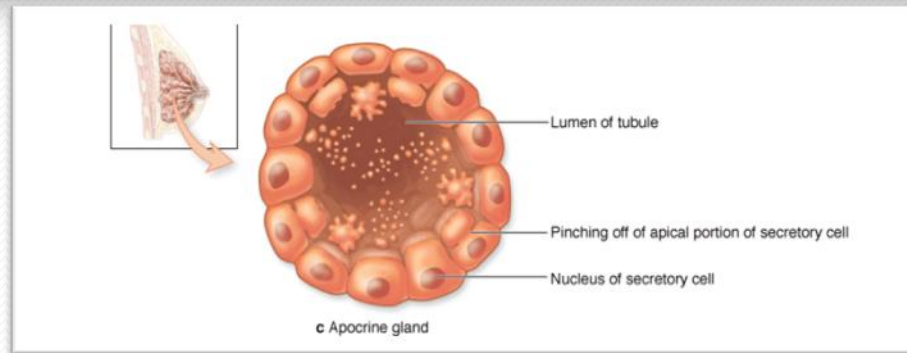
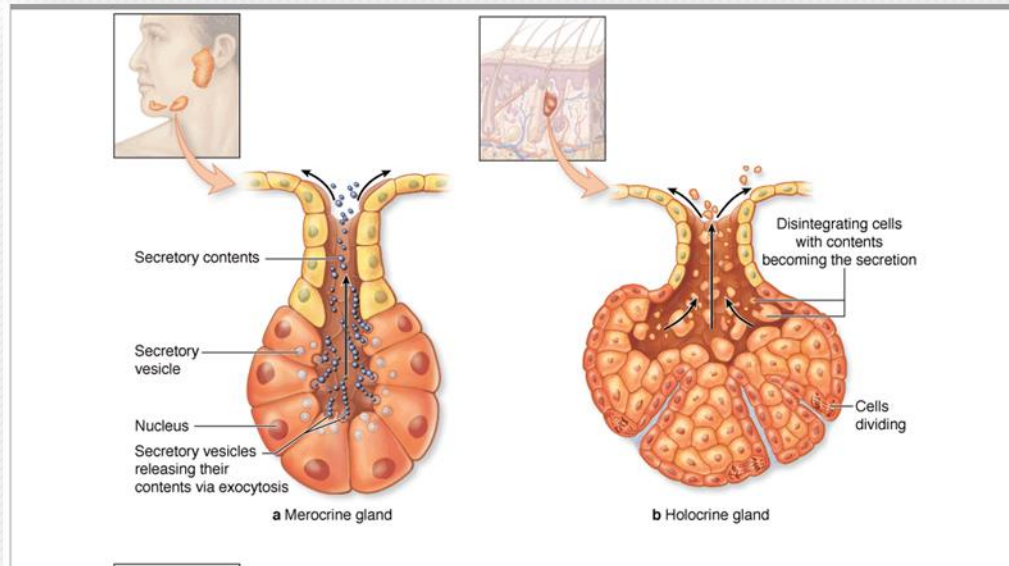


6- Compound acinar : Branching ducts with acinar secretory unites(e.g,. Parotid salivary gland and mammary glands ).



- Exocrine glands are also classified functionally according to the way the secretory products leave the cell :
- 1- Merocrine secretion (sometimes called eccrine) involves typical exocytosis of proteins or glycoproteins. This is the most common mode of secretion. (Figure17)
- 2- Holocrine secretion involves the cell filling with secretory product and then the whole cell being disrupted and shed. This is best seen in the sebaceous glands of skin (Figure18).
- 3-, apocrine secretion, In an intermediate type ,the secretory product is typically a large lipid droplet and is discharged together with some of the apical cytoplasm and plasmalemma, is seen in mammary glands. (Figure19)





Figuer(19)



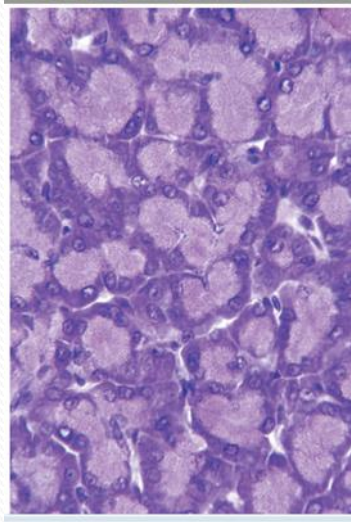
- Exocrine glands with merocrine secretion can be further categorized as either serous or mucous according to the nature of the proteins or glycoproteins secreted and the resulting staining properties of the secretory cells. The acinar cells of the pancreas and parotid salivary glands are examples of the serous type which secrete digestive



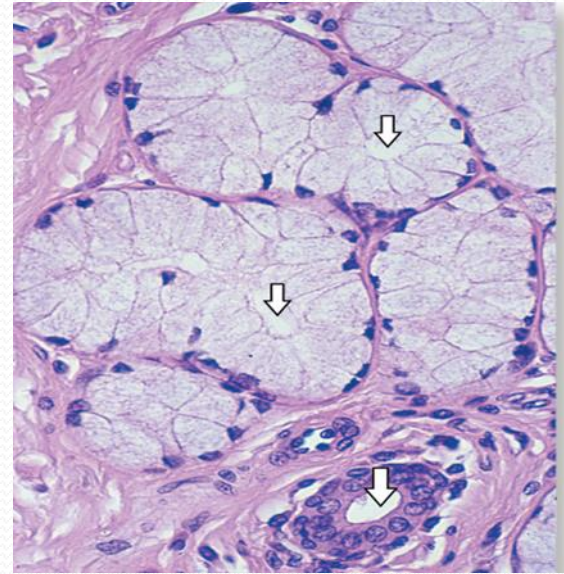


- The basal ends of serous cells have well-developed RER and Golgi complexes and the cells are filled apically with secretory granules in different stages of maturation as (figure 20) , Mucous cells, such as goblet cells, while also rich in RER and Golgi complexes are filled apically with secretory granules containing strongly hydrophilic glycoproteins called mucins as figure (21).





Figure(20)



figure(21)



# References

- Junqueira's ,L.C and Carneiro ,J.(2014):Basic Histology ,tText and Atlas3 th ed.McGraw-Hill Paulo,pp(70-90).
- Junqueira's ,L.C and Carneiro ,J.(2017):Basic Histology ,tText and Atlas3 th ed.McGraw-Hill Paulo,pp(80-95

