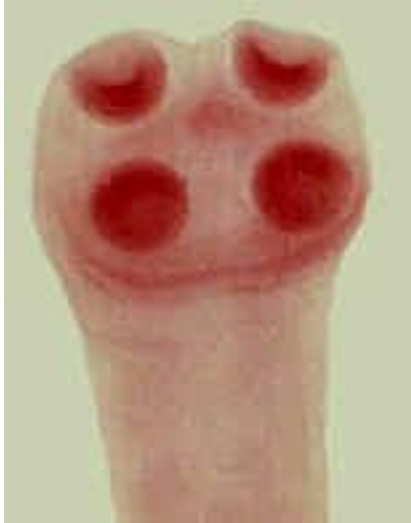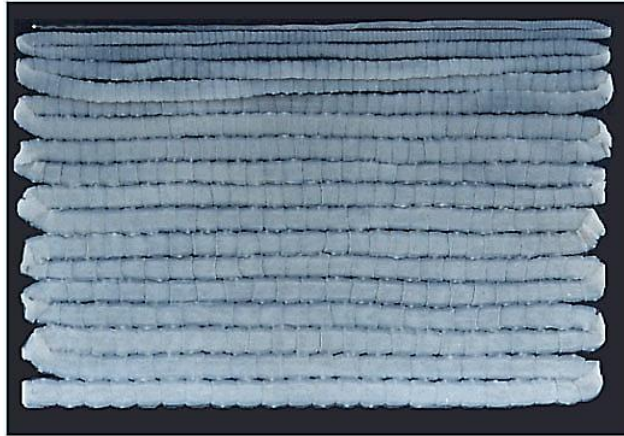


## *Taenia saginata*



*Scolex*



*Whole worm*

The beef tapeworm, *Taenia saginata* Goeze, 1782 was widely known in ancient Egypt and Greece and was prevalent in Europe. Leuckart in 1862 first demonstrated that human infection resulted from eating infected raw beef. Beef tapeworm infection is cosmopolitan among beef-eating peoples.

### **Morphology, Biology and Life Cycle**

The adult worm develops typically in the middle third of the small intestine, attached to the mucosa. The average length of the relaxed worm is approximately 5 meters, although there are records of specimens of far greater lengths. There are 1000 to 2000 proglottids, of which form one-third to one-half are gravid. Usually only a single specimen occurs in an infection, but there may be two or more.

The fully developed worm is delicate anteriorly and more robust posteriorly. The rhomboidal scolex. Instead of hooklets on a rostellar prominence as in *Taenia solium* there is a slight apical depression. The terminal proglottids become separated from the strobila and actively migrate out of the bowel or are evacuated

in the stool with only partial loss of eggs, which are essentially spherical, measure 31 to 43 microns in diameter, have a thin, transparent outer envelope.

The evacuated gravid segments extrude the eggs; disintegrate on moist earth or in sewage, freeing the eggs which are ready for development in the intermediate host. Cattle grazing on infested ground pick up the eggs, which hatch in duodenum. The emerging embryos reach skeletal muscles or the heart, where they transform in 60 to 75 days into the typical cysticercus stage (*Cysticercus bovis*). Thereafter, for a period of more than a year persons who eat the raw infected beef are subject to infection. In 3 to 6 months after human exposure the complete worm has developed and gravid proglottids are being shed.

### **Pathogenicity and Symptomatology**

Infection with *T. saginata* is ordinary symptomless and except for the discomfort, inconvenience or embarrassment resulting gravid proglottids crawling out of the anus. However, towards the end of the prepatent period there are sometimes diarrhea, and abdominal cramps, and moderate loss of weight. Appendicitis due to the lodging of gravid proglottids in the appendiceal lumen has been reported. Rarely a mass of tangled worms may cause acute intestinal obstruction.

### **Diagnosis**

Eggs of *T. saginata* are often found in the feces. They are indistinguishable from those of *T. solium*. In all mature infections gravid proglottids are being evacuated. The unpreserved proglottids have number of main lateral arms of the uterus (15 to 20, usually 18) on each side of the main uterine stem. This constitutes specific diagnosis. The gravid proglottids deposit eggs in the anus and perianal area as they crawl from the rectum. For this reason the diagnosis may be made by use of an adhesive cellophane tape technique, as with enterobiasis.

### **Epidemiology**


Cattle acquire the larval stage of *T. saginata* by grazing on moist pasture land polluted by feces containing the fully embryonated eggs of this tapeworm.

Under suitable conditions of moisture and temperature the eggs may remain viable for 6 months. Approximately 2 to 3 months after the cattle are exposed the larva have matured and the meat is infective. After a year or more, however, they often become calcified. In some human communities infections result from eating frankly raw beef. In most endemic it is due to consumption of undercooked steaks or burgers.

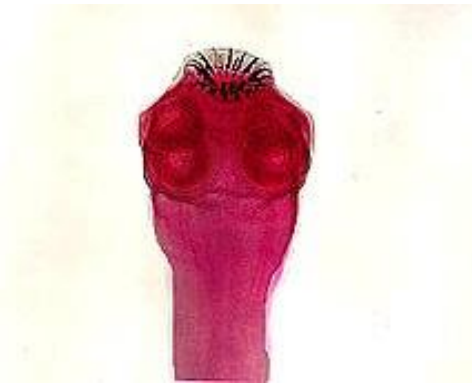## Control

Basically, control of teniasis consists in sanitary disposal of human feces, so that eggs of *T.saginata* in excreta or community sewage do not reach pastures where cattle graze. Beef which has been kept 24 hours or longer in a deep freezer is sterilized. Likewise, heating the meat to 65° C is a safeguard.

## *Taenia solium*



**Mature proglottids**



**Scolex**

The larval stage of the pork tapeworm (*Cysticercus cellulosae*) was described from swine by Greek naturalists. Pork tapeworm infection is cosmopolitan wherever raw or inadequately processed pork is eaten.

## Morphology, Biology and Life Cycle

In most respects, *Taenia solium* resembles *T.saginata*, but *T.solium* is shorter, usually having a length of less than 3 meters, due to a smaller number of proglottids (fewer than 1000) and shorter gravid proglottids. There is a double circle of alternating large and small hooklets. Eggs of *T. solium* are indistinguishable from those of *T. saginata*.

Gravid proglottids passed in the stool or actively migrating out of the anus of the host discharge the eggs or disintegrate when deposited on the ground. To develop, the eggs must be ingested by hogs. The embryos reach skeletal muscle and myocardium. Here they transform in 2 to 3 months into cysticercus larvae (*Cysticercus cellulosae*).

When human eat pork containing viable cysticerci, the larvae are digested out of the meat, the heads become attached to the walls of the proximal portion of the ileum and in approximately 3 months each develops into a complete worm.

### **Pathogenicity and Symptomatology**

The adult *T. solium* in the human small intestine produces the same pathological processes and clinical manifestation as *T. saginata*. However, because of its shorter length there is less likelihood that intestinal obstruction will develop.

### **Diagnosis**

Although eggs of *T. solium* are occasionally found in the host's stools or in anal swabs, a specific diagnosis is based on demonstration of the relatively small number of main lateral arms of the uterus (7 to 13, usually about 9) in gravid proglottids compressed between two glass slides.

### **Treatment**

Treatment of taeniasis may include administration of praziquantel (5-10 mg/kg, single-administration) or niclosamide (2 g, single-administration, followed after 2 hours by a laxative).

### **Epidemiology**

Human infection with the adult *Taenia solium* results from eating essentially raw pork containing viable *Cysticercus cellulosae*. The hog is the usual source from which man obtains the larval stage, and man is the only natural host of the adult worm. However, man is also a suitable host for the *cysticercus*.

## Control

The serious, frequently disabling and at times fatal consequences of human cysticercosis resulting from larval *T. solium* infection indicate the peculiar need for control of this infection. In endemic areas human feces should not be deposited in locations where hogs have access to them.

